

Images in medicine

Images of bronchiectasis in thoracic surgery

Grégoire Kouakou Ayegnon^{1,§}, Christophe Gueu Ménéas¹

¹Department of Cardio Vascular and Thoracic Diseases, Bouaké University Teaching Hospital, Bouaké, Côte d'Ivoire

[§]Corresponding author: Grégoire Kouakou Ayegnon, Department of Cardio Vascular and Thoracic Diseases, Bouaké University Teaching Hospital, Bouaké, Côte d'Ivoire

Key words: Bronchiectasis, tuberculosis sequelae, lobarbronchiectasis

Received: 17/05/2015 - Accepted: 02/09/2015 - Published: 09/09/2015

Pan African Medical Journal. 2015; 22:20 doi:10.11604/pamj.2015.22.20.7085

This article is available online at: <http://www.panafrican-med-journal.com/content/article/22/20/full/>

© Grégoire Kouakou Ayegnon et al. The Pan African Medical Journal - ISSN 1937-8688. This is an Open Access article distributed under the terms of the Creative Commons Attribution License (<http://creativecommons.org/licenses/by/2.0>), which permits unrestricted use, distribution, and reproduction in any medium, provided the original work is properly cited.

Image in medicine

The bronchial dilations also called bronchiectasis are permanent and irreversible increase in the bronchial tubes. They can be extended or localized especially in pulmonary tuberculosis sequelae. This affection is serious, because it is at the origin of an embarrassing obstructive pulmonary disease, leading to social discomfort and preferentially in Côte d'Ivoire, it affects young subjects between 30 and 40 years old and former tuberculous. The place of surgery is still debated. Mr Coulibaly is 30 years old, hospitalized in the Thoracic Surgery Department of BouakeTeaching Hospital for pulmonary tuberculosis sequelae type symptomatic left lower bronchiectasis lobe and well localized (A). After a satisfactory preoperative evaluation, we performed a left lower lobectomy on this patient. Transection in the third world of the bronchial lower lobe resected reveals multiple tubular dilations with thickened wall

containing purulent secretions (B). The specimen was sent to the pathology laboratory for confirmation of tuberculosis sequelae.

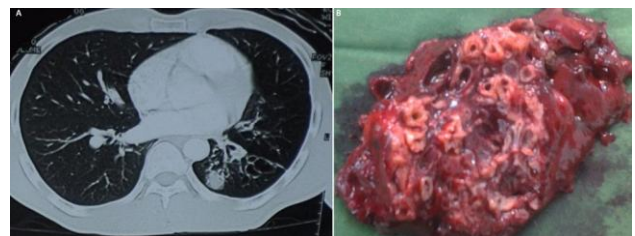


Figure 1: (A) thoracic Scanshowing the localized left lower lobarbronchiectasis; (B): bronchiectasis of lower left lobar surrinfected, viewed after transection of the left lower lobectomy of lung