

Images in medicine

Mediastinal and peripheral lymphadenopathy

Khaoula Elatiqi^{1,&}, Najiba Yassine¹

¹Department of Respiratory diseases, Ibn roshd University Hospital, Casablanca, Morocco

[&]Corresponding author: khaoula Elatiqi, Department of Respiratory diseases, Ibn roshd University Hospital, Casablanca, Morocco

Key words: Lymphadenopathy, lymphoma, tuberculosis

Received: 24/06/2015 - Accepted: 12/11/2015 - Published: 03/12/2015

Pan African Medical Journal. 2015; 22:332 doi:10.11604/pamj.2015.22.332.7350

This article is available online at: <http://www.panafrican-med-journal.com/content/article/22/332/full/>

© Khaoula Elatiqi et al. The Pan African Medical Journal - ISSN 1937-8688. This is an Open Access article distributed under the terms of the Creative Commons Attribution License (<http://creativecommons.org/licenses/by/2.0>), which permits unrestricted use, distribution, and reproduction in any medium, provided the original work is properly cited.

Image in medicine

A 32-year-old man, with no history of cigarette smoking, had four weeks history of non productive cough, chest pain and myalgias. Physical examination revealed a painless bilateral cervical lymphadenopathy, the respiratory examination was normal. Chest radiography showed an enlarged upper and middle mediastinum (A). Computed tomography (CT) of the thorax showed a large and non homogeneous mass in the anterior and middle mediastinum and a small pericardial effusion, with displacement of vascular structures (B). Laboratory analysis revealed an elevated lactate dehydrogenase level of 690 IU per liter. The excisional biopsy of the left cervical lymph node revealed a caseating and necrotizing granulomatous lesions and confirmed a diagnosis of lymph node tuberculosis. The biopsy of the right cervical lymph node established a B-cell non-Hodgkin lymphoma, and so a rare association with tuberculosis. The patient received anti-tuberculosis therapy. The regimen was based on two months of ethambutol, rifampicin, pyrazinamide and isoniazid, followed by four months of rifampicin

and isoniazid. He received also chemotherapy with cyclophosphamide, adriamycin, vincristine and prednisolone. The patient presented, two months later with clinical and radiographic improvement.

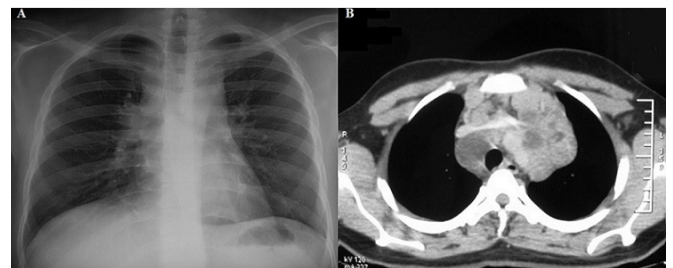


Figure 1: (A) a chest radiography showing an enlarged mediastinum; (B) a thoracic CT showing a large and inhomogeneous mass in the mediastinum