

## **Massive rectal bleeding from colonic diverticulosis**

**\*Olokoba A B<sup>1</sup> and Obateru O A<sup>2</sup>**

### **Case Report**

#### **ABSTRACT**

**Objectives:** This is to describe a case of colonic diverticulosis causing massive rectal bleeding in an elderly Nigerian man.

**Case report:** We highlight a case of a 79 year old man who presented with massive rectal bleeding due to colonic diverticulosis from our centre. Colonoscopy identified multiple diverticula in the proximal rectum, sigmoid, descending and transverse colon. The diverticula were more in the descending colon and also oozing blood. He was worked up, and had surgery for hemicolectomy due to massive blood loss following failure of initial conservative management.

**Conclusion:** Colonic diverticulosis may cause massive rectal bleeding severe enough to require hemicolectomy. Only few similar cases have been reported in this part of the continent.

**Keywords:** Colon, rectal bleeding, diverticulosis, colonoscopy

\*Corresponding author: Dr. A. B Olokoba. E-mail: drabolokoba@yahoo.com

<sup>1</sup>Gastroenterology unit, Department of Medicine, University of Ilorin Teaching Hospital, Ilorin, Nigeria.

<sup>2</sup>Department of Medicine, Federal Medical Centre, Lokoja, Nigeria

## Massive colique saignement rectal diverticuloses

\*Olokoba A B<sup>1</sup> and Obateru O A<sup>2</sup>

### un rapport de cas

#### RÉSUMÉ

**Objectif:** Cette étude décrit un cas de diverticulose colique provoqué d'importants saignements du rectum chez un homme Nigérian – personne âgée.

**Rapport De Cas:** Nous mettons un cas d'un homme de 79 ans qui présente une hémorragie rectal massive en raison de la diverticulose colique de notre centre coloscope identifie diverticules multiples dans le rectum proximal, sigmoïde, descendant et transversal diverticules colons. Les diverticules étaient plus dans le colon descendant et suintant aussi du sang. Il a été traité, et subi une intervention chirurgicale pour hem colectomie l'échec d'un traitement conservateur initial.

**Conclusion:** Diverticuloses colique peut provoquer des saignements du rectum massif suffisamment graves pour nécessiter hémicolectomie seulement quelques cas similaires ont été signalés de cette partie du continent.

**Mots Clés:** Colon, saignement rectal, diverticulose, la coloscopie.

\* Auteur correspondant: Dr. A. B Olokoba. E-mail: drabolokoba@yahoo.com

<sup>1</sup>Gastroenterology unit, Department of Medicine, University of Ilorin Teaching Hospital, Ilorin, Nigeria.

<sup>2</sup>Department of Medicine, Federal Medical Centre, Lokoja, Nigeria

## **INTRODUCTION**

Diverticular disease of the colon is the out-pouching of the mucosa and submucosa through weak areas in the muscular walls of the large bowel to form narrow-necked pouches (1). It is well recognized in western countries (2). The true incidence of diverticulosis of the colon is not known. But comparison of autopsies and barium enema studies have indicated increasing world prevalence (3). It has been reported that diverticular disease is on the increase in Africa (4). Colonic diverticular bleeding (CDB) in adults, is the commonest cause of overt lower gastrointestinal (GI) bleeding (5). CDB can present as brisk haematochezia (bright red or maroon-coloured blood), accounting for 30-50% of cases of massive rectal bleeding (5,6). Right sided diverticula, although much less common than left sided ones, are likely responsible for 60% of cases of colonic diverticular bleeding (6). Segmental weakening of the associated vasa rectum may result from traumatic forces within the lumen of the diverticulum (7). Rupture of these vessels into the intestinal lumen results in rectal bleeding ranging from intermittent spotting to life-threatening haematochezia (8). Risk factors for diverticular bleeding include advanced age, hyper-uricaemia, systemic hypertension (SBP), concomitant chronic medical disorders of liver and heart, and steroid or NSAID use (6,9). Complications from colonic diverticulosis include diverticulitis, lower gastrointestinal (GI) haemorrhage, hypertrophy and obstruction, pericolic abscess, perforation and vesico-colic fistula formation, and peritonitis (4).

Endoscopic examination (colonoscopy) is necessary to localize and treat this condition. In situations where colonoscopy is not possible or has repeatedly failed to localize the bleeding site, angiography and nuclear scintigraphy may be used (10). Other diagnostic modalities include barium enema, computerised tomography (11). Endoscopic techniques

such as haemo-clips, thermocoagulation, and injection therapy may be effective in achieving haemostasis and avoiding precarious surgery (10).

## **CASE REPORT**

The patient was a 79-year old retired civil servant with a history of diabetes mellitus (DM) and SBP who presented to the hospital with a history of recurrent rectal bleeding. Bleeding was mainly dark altered blood but occasionally bright red. He had no anal pain, protrusion or faecal incontinence. No weight loss. Physical examination revealed an obese but pale elderly man. The digital rectal examination was unremarkable although the examining finger was stained with blood. He had a complete blood count done which showed a packed cell volume (PCV) of 23%, and microcytosis. Liver function tests, and abdomino-pelvic ultrasound were normal.

He was managed conservatively with the transfusion of four units of whole blood, which raised his PCV to 32%. He was also placed on a high fibre diet, and intravenous Ciprofloxacin and Metronidazole. The rectal bleeding stopped within two days of admission, and he was discharged home three days later on haematinics, and his routine drugs which were glucophage, glibenclamide, amlodipine, lisinopril, and clopidogrel. He was asked to do colonoscopy, and present the result of same to the out-patient clinic. Eight days later (after discharge from the hospital), he had repeat episodes of haematochezia which necessitated an emergency colonoscopy carried out according to standard protocol. His PCV had also reduced to 20%. At colonoscopy, multiple diverticula were seen in the proximal rectum, sigmoid, descending and transverse colon. The diverticula were more in the descending colon and also oozing blood (fig. 1 and 2). Upper GI endoscopy carried out was unremarkable. He was subsequently transferred to the surgeons who worked him up for hemi-colectomy due to massive rectal bleeding and failure of the

initial conservative management. He has had surgery, and he is doing well.

## DISCUSSION

Most people with uncomplicated diverticula are asymptomatic and it has been estimated that only 20% of individuals harbouring diverticula will present with symptoms and signs of the disease(4). However those who are symptomatic may experience abdominal discomfort and pain, bloating, change in bowel habit, bleeding and fever.

Colonic diverticulosis occur more commonly after the age of 60years, and predisposes individuals to GI haemorrhage in up to 5% of patients (6,8,12).With an incidence of less than 2% in people less than 30 years; 50% in people over 50; and 70% in people over 80 years.(8)The causes of massive lower GI haemorrhage, one of which is colonic diverticula is bleeding distal to the ligament of Treitz that requires the transfusion of three or more pints of blood over 24 hours(12). Our patient was a 79years who came in with recurrent massive rectal bleeding, necessitating transfusion of four units of blood. Our patient also had no abdominal complains except for the painless rectal bleeding. This is in contrast to previous reports where patients with CDB are reported to have abdominal symptoms such as pain, bloating, change in bowel habit etc (4). Right sided colonic diverticula, although much less common than the left are more likely to bleed in 60% of cases (6,13).This is in contrast to the findings in our patient when colonoscopy was carried out, in which the diverticula were more at the descending colon-left sided, and were found to be bleeding. Our patient had other risk factors which could predispose to CDB such as ageing, SBP, and DM. This is similar to findings in the literature where ageing, and co-morbid medical conditions predispose individuals with colonic diverticulosis to bleeding (6, 9). Most episodes of lower GI haemorrhage from colonic diverticulosis tend to cease spontaneously (8). On the first occasion, our

patient's rectal bleeding ceased spontaneously with conservative management and blood transfusion. He did not require any procedure to secure haemeostasis. However, on the second occasion with recurrence of the rectal bleeding, he was offered emergency colonoscopy, and subsequently transferred to the surgeons who planned him for hemicolectomy amongst other management.

## CONCLUSION

Bleeding from Colonic diverticula could be massive and life threatening, and may require surgical intervention. Only few similar cases have been reported in this part of the continent.

## REFERENCES

1. Kang JY, Melville D, Maxwell JD. Epidemiology and management of diverticular disease of the colon. *Drugs Aging* 2004;21(4):211-228.
2. Hussain A, Mahmood H, Gok Ulah Krishna S, Shamsi E. Complicated diverticular disease of the colon, do we need to change the classical approach, a retrospective study of 110 patients in southeast England. *World J Emerg Surg* 2008;3:5.
3. Richter S, vd Linde J, Dominok GW. Diverticular disease. Pathology and clinical aspects based on 368 autopsy cases. *Zentralbl Chir* 1991;116(17):991-998.
4. Madiba TE, Mokoena T. Pattern of diverticular disease among Africans. *East Afr Med J* 1994;71(10):644-646.
5. Browder W, Cerise EJ, Litwin MS. Impact of emergency angiography in massive lower gastrointestinal bleeding. *Ann Surg* 1986;204:530.
6. Stabile BE, Arnell TD. Diverticular disease of the colon. In: *Current diagnosis and treatment in Gastroenterology*. 2<sup>nd</sup> Ed. Friedman SL, McQuaid KR, Grendell JH(eds). New York, McGraw- Hill, 2003:436-

- 451.
7. Adams JB, Margolin MD. Management of colonic diverticular haemorrhage. *Clin Colon Rectal Surg* 2009;22(3):181-185.
  8. Maykel J, Opelka FG. Colonic Diverticulosis and Diverticular haemorrhage. *Clin Colon Rectal Surg* 2004;17(3)195-204.
  9. Jensen A, Harenberg S, Grenda U, Elsing C. Risk factors for colonic diverticular bleeding: a westernized community-based hospital study. *World J Gastroenterol* 2009;15:457-461.
  10. Barnet J, Messmann H. Lower gastrointestinal bleeding. *Best pract Clin Gastroenterol* 2008;22(2):295-312.
  11. Hemming J, Floch M. Features and management of colonic diverticular disease. *Curr Gastroenterol Rep* 2010;12(5):399-407.
  12. McGuire H H, Haynes B W. Massive hemorrhage from diverticulosis of the colon: guidelines for therapy based on bleeding patterns observed in fifty cases. *Ann Surg.* 1972;175:847-853.
  13. Janes SE, Meagher A, Frizelle FA. Management of diverticulitis. *BMJ* 2006; 332(7536):271-275.

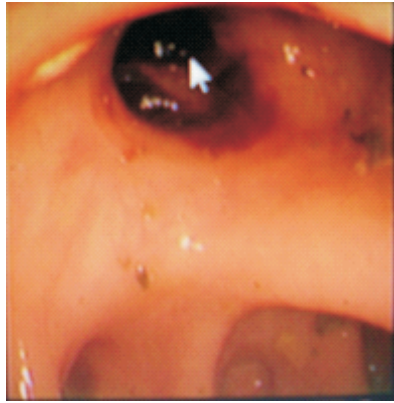


Fig. 1 showing a bleeding descending colon diverticulum (white arrow)

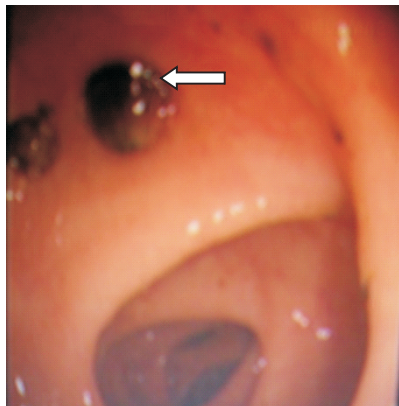


Fig. 2 showing another bleeding descending colon diverticulum (white arrow)