

# Traumatic brain injury in children

Marc Coughlan MBChB (Cape)

Graham Fieggen MBChB (Cape) MSc (Lond) FCS

Division of Paediatric Neuroscience (Neurosurgery)

University of Cape Town and Red Cross Children's Hospital

Correspondence: GFIEGGEN@ich.uct.ac.za

Key words: Traumatic brain injury, non-accidental injury, intracranial pressure

## Highlights / Hoogtepunte

- How to classify brain injuries according to clinical severity, mechanism of action of the injury and pathology.
- What are the challenges and treatment priorities in managing traumatic brain injuries in children? And who should be scanned?
- Strategies to lower and/or maintain intracranial pressure.
- Hoe moet breinbeserings geklassifiseer word op grond van kliniese ernstigheid, meganisme van die besering en die patologie?
- Wat is die uitdagings en prioriteite wanneer 'n breinbesering in kinders behandel moet word? En wie moet geskandeer word?
- Strategieë om intrakraniale druk te verlaag en/of instand te hou.

SA Fam Pract 2003;45(5):32-41

## INTRODUCTION

Trauma remains a leading cause of death and disability among South African children;<sup>1</sup> major trauma often involves the central nervous system (CNS) and this impacts greatly on morbidity and mortality.

As the developing brain is unique structurally when compared to the adult brain, so too are its array of physiological responses. Current thinking emphasises the concept of *traumatic brain injury* (TBI) rather than the non-specific term "head injury". Many of the principles of management of TBI are similar to those that obtain in adults but there are important differences; this review will highlight issues specific to children.<sup>2,3</sup>

## AGE-RELATED FACTORS

The factors which distinguish head injury in children from head injury in adults may be summarised as follows:

### *Anatomy:*

The unique anatomical relationship of the head to body ratio (15% body weight in the neonate compare to 3% in the adult), weak neck musculature and thin

skull make infants more susceptible to CNS injury.

### *Pathology:*

Mass lesions such as extradural, subdural and intracerebral haematomas occur with a higher incidence in adults (30-40%) than in children (15-20%). Skull fractures in children are less commonly associated with extradural haematomas than in adults. Children more frequently present with diffuse injury and severe cerebral swelling, with resultant raised intracranial pressure (ICP).

### *Neurobiology:*

Perhaps the greatest difference is the fact that the brain is still developing with ongoing myelination, dendritic outgrowth, synaptogenesis and acquisition of a myriad of skills. This is easily disrupted by any major insult.

### *Outcome:*

An increased mortality following severe traumatic brain injury has been reported in young children (under 4 years old) who more commonly develop diffuse swelling compared to adolescents and adults. Older children may, however, fare better than adults.

## EPIDEMIOLOGY

A bimodal distribution of head injuries in children has been noted, namely early childhood (under 5 years of age) and mid to late adolescence. Over the age of 5 years, males predominate by a factor of 2-5 times with a preponderance amongst lower socio-economic groups.

## CLASSIFICATION

Head injury may be classified on the basis of

- Clinical severity
- Mechanism of injury
- Pathology

Traumatic brain injuries are graded as mild, moderate or severe on the basis of the level of consciousness or Glasgow coma scale (GCS) score after resuscitation<sup>4</sup> (Table I). This is difficult to apply to the pre-verbal child and a number of infant scales have been proposed, such as the Chicago Children's Coma Score<sup>5</sup> (Table II).

Mild traumatic brain injury (GCS 13-15) is in most cases a concussion and there is full neurological recovery, although many of the patients have

Table I: Glasgow Coma Scale (GCS) Score<sup>4</sup>

Eye opening:		Verbal response:		Motor response:	
4	spontaneous	5	orientated	6	obeys commands
3	speech	4	confused	5	localises pain
2	pain	3	inappropriate	4	flexor withdrawal
1	verbal	2	incomprehensible	3	abnormal flexion
		1	none	2	extension
		1	none		

Table II: Chicago Children's Coma Scale (CCS)<sup>5</sup>

Ocular response:		Verbal response:		Motor response:	
4	pursuit	3	cries	4	flexes and extends
3	extra ocular muscles intact reactive pupils	2	spontaneous respiration	3	withdraws
2	fixed pupils or extra ocular muscles impaired	3	apnoeic	2	hypertonic
1	fixed pupils and extra ocular muscles paralysed	1	flaccid		

short-term memory and concentration difficulties. In moderate brain injury (GCS 9-13) the patient is often lethargic or stuporous, and in severe injury (GCS 3-8) the patient is comatose, unable to open his or her eyes or to follow commands.

Although duration of post-traumatic amnesia is a useful yardstick in adults, this is difficult to apply in young children.

### MECHANISMS OF INJURY

The biomechanics of paediatric TBI have been reviewed recently.<sup>6</sup> In children the majority of injuries occur secondary to motor vehicle accidents (MVAs), with the actual percentage of MVA-related accidents increasing with age. Among infants, toddlers and young children, the other major causes include assaults, child abuse and falls. Penetrating injuries are rare in childhood although one may see accidental transoral or transorbital injuries due to pencils and the like.

### PATHOPHYSIOLOGY

The result of traumatic brain injury is not a single pathologic event but a series of pathophysiologic changes that vary

both in severity and over time such that no two head injuries are quite the same. Current discussions of the pathology of head injuries have tended to classify the brain injury as focal or diffuse.

*Focal* lesions include cerebral contusions and lacerations, haematomas, brain stem trauma and injuries to the cranial nerves and pituitary stalk.

*Diffuse* brain injuries include cerebral concussion and diffuse axonal injury. Diffuse injuries are more common in children than focal injuries and the vast majority of traumatic injuries are due to *closed* head injuries; *open* injuries such as gunshots and stabs are much less common than in adults.

Another concept emphasises the existence of primary and secondary injury, and these are considered stages in the evolution of head trauma. By definition, *primary head injury* occurs at the time of impact and *secondary injury* refers to the cascade of biochemical and physiologic events within the injured brain. Secondary responses which occur after traumatic brain injury, include:

- loss of cerebral autoregulation.
- breakdown of the blood brain barrier
- intracerebral oedema
- ischaemic brain injury.

Injury can also be augmented by secondary extracerebral insults, particularly

- hypoxaemia
- hypotension

Many authors have reported a strong association between diffuse brain swelling and either hypoxaemia or early hypotension and suspect that these factors are pivotal in the pathogenesis of raised ICP seen in children.<sup>7</sup>

### SPECIFIC INJURIES

#### *Non-accidental injury (NAI)*

It has been estimated that up to one-quarter of all hospital admissions for head injury in children younger than 2 years of age result from deliberately inflicted trauma and these children suffer disproportionately severe injuries. The original description of "whiplash shaken-baby syndrome" by Caffey in 1974 drew attention to the importance of rotational acceleration but subsequent work emphasised the frequent occurrence of impact in causing a deceleration injury. There may be no external evidence as the child may be thrown onto a soft surface.<sup>8</sup> More recent work has highlighted the central role of hypoxic brain injury.<sup>9</sup>

This syndrome is characterised by injuries that are often multiple and diffuse. The history is probably the most important factor in making the diagnosis, often in a paradoxical sense in that the less convincing the explanation for the child's injuries, the greater the likelihood of NAI.

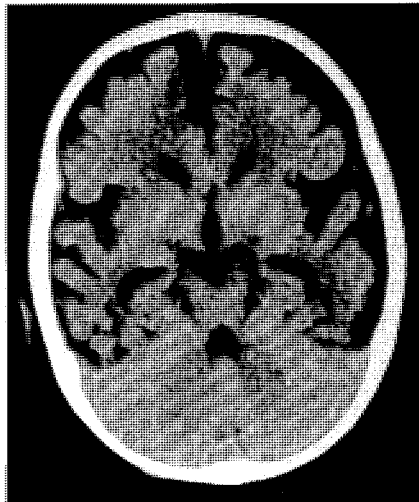
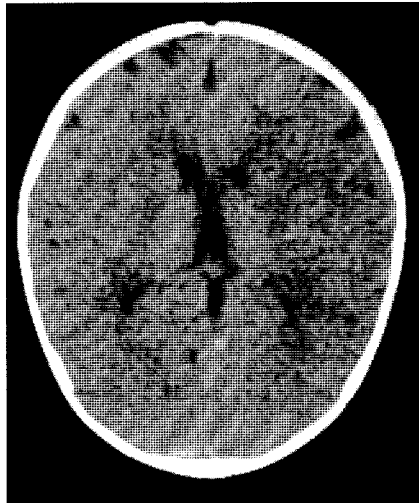
Characteristic brain injuries include subarachnoid and subdural haemorrhage and skull fractures which are often bilateral, multiple and cross sutures.<sup>10</sup> CT scan may show evidence of previous injury including chronic subdural collections.

*Retinal haemorrhages* occur in 65-95% and are due to multiple repeated blows, violent shaking of the head and massive thoracic compression. A *skeletal survey* is mandatory and this may detect the characteristic fractures of long bones or ribs. It is incumbent on all health care workers to actively investigate suspected child abuse as this is a disease that is both recurrent and devastating.

Long-term follow up of these children often discloses severe disability

and marked brain atrophy may be evident on CT scan (Figure 1).

**Figure 1: Axial head CT scan of a 3-month-old victim of NAI (a) and follow up 2 months later showing profound atrophy (b)**

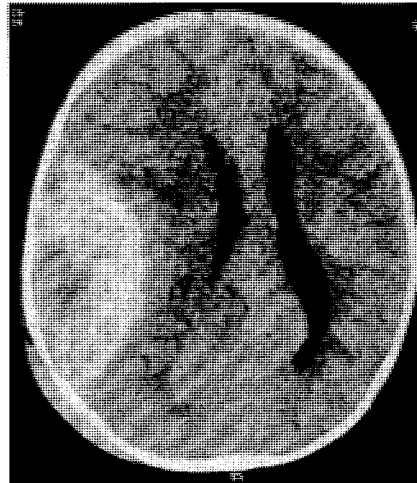


### Haematomas

Extradural haematomas are most common; in adults the usual cause of the haemorrhage is arterial in origin whereas venous or bony injury are more common causes in children (Figure 2). This means that the presentation may be subacute with symptoms only a couple of days after the injury.

Although there is ongoing debate about the value of skull X-rays, the presence of a fracture in a child should lower one's threshold for obtaining a CT scan. This is particularly the case in the presence of a linear occipital fracture as posterior fossa extradurals are notoriously difficult to diagnose clinically.<sup>11</sup>

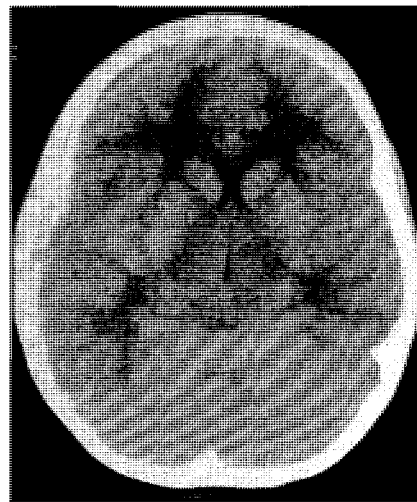
**Figure 2: Large right sided extradural haematoma complicating a linear fracture**



Subdural haematomas are less common in children (Figure 3). They are often associated with non-accidental injury but may also be seen in high speed MVAs where the haematoma is due to a burst lobe.

Some acute subdural haematomas secondary to traumatic injury are a result of a tear in a convexity-bridging vein.

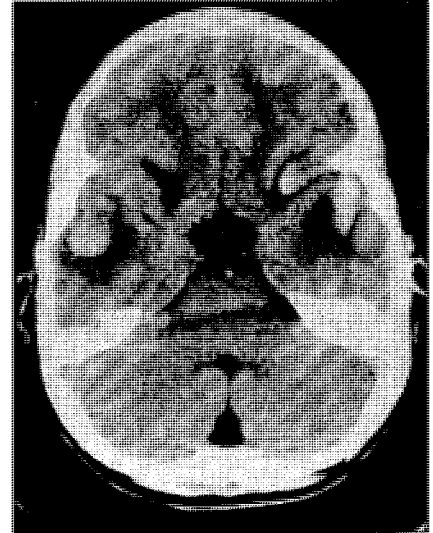
**Figure 3: Right sided acute subdural haematoma**



As the cause of this is a low impact injury and a venous haematoma, it accumulates slowly with resultant mass effect and compression. As a consequence the child can present with seizures and focal neurological signs prior to a deteriorating level of consciousness.

Focal contusions may be seen on CT scans in children with severe injury, particularly on follow-up CT scans (Figure 4).

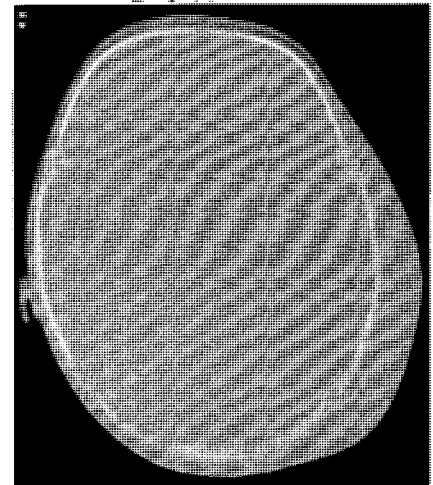
**Figure 4: Multiple contusions in the frontal and temporal lobes following a MVA**

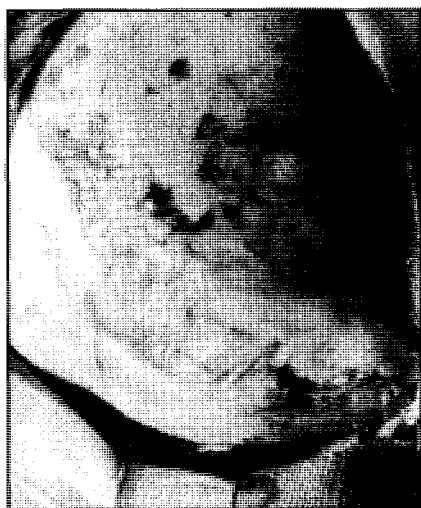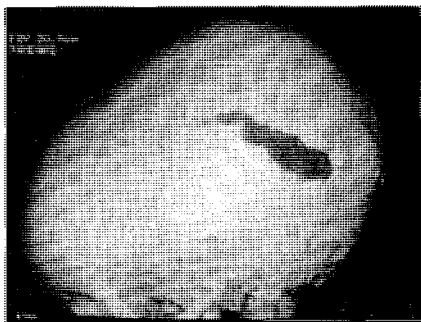


### Skull fractures

Operative management is not necessary for closed linear skull fractures, or even minimally depressed fractures, unless there is an underlying pathology that requires intervention. However, infants with linear fractures should be followed up carefully to detect the development of a growing fracture, which is characterised by a dural tear and diastasis of the fracture line (Figure 5). In compound depressed fractures, which are significantly in-driven, there may be an associated dural tear. The risk of intracranial infection is increased the longer the fracture is left open.<sup>12</sup>

**Figure 5: Initial CT showing a linear skull fracture in an infant (a). A year later there was a palpable skull defect, shown on the 3D CT scan (b) and at surgery (c)**





Skull base fractures are usually diagnosed clinically when there is CSF rhinorrhoea or otorrhoea or signs such as subconjunctival haemorrhage or mastoid ecchymosis (Battle's sign).

#### CHALLENGES IN MANAGEMENT

The three biggest challenges are

- The frequent problem of a young child with a minor injury.
- Who should be referred for CT scan.
- The child with a severe injury.

#### Minor TBI

One of the most common emergency room problems is the child who has fallen from a bed or playground apparatus or had a minor play or sport-related impact.<sup>13</sup> Transient concussion may occur, vomiting is frequent and there may even be an early seizure (so-called "impact seizure"). The vast majority of these children are absolutely well on examination and most are discharged home with a head-injury form after their caregiver has been advised of possible complications. Some may warrant admission for a short period of neurological observation.

The problem is that the occasional

child with an apparently minor injury may have a poor outcome, the "talk and die" scenario.<sup>14</sup> It is important to identify children at special risk such as those with an underlying medical condition such as a blood dyscrasia or ventriculo-peritoneal shunt or child abuse.

#### Who to scan?

The use of skull radiographs has been debated at length but this is still a useful option in a peripheral hospital as long as one realises that absence of a fracture does not exclude a significant brain injury.

Absolute indications for an urgent CT scan include:

- Depressed level of consciousness
- Deteriorating level of consciousness
- Focal neurological signs
- Evidence of increased ICP
- Penetrating injury.

Delayed CT scan may be indicated for

- Seizures, especially if focal or repeated.
- Ongoing vomiting.
- Base of skull fracture.

#### Severe TBI

Apart from treatment, a very important area on which to focus attention considering head injuries is prevention. This has three stages:

1. to stop the accident occurring;
2. to reduce the injury sustained on impact;
3. to ameliorate the secondary injury that follows.

Probably the greatest impact lies in primary prevention such as enforcement of laws on drunk and reckless driving, use of child restraints, etc. This is an immense challenge in South Africa and has been taken up by organisations such as the Child Accident Prevention Foundation (CAPFSA). Educating children is an important part of this strategy.

Before the patient reaches hospital, an organised system which allows rapid resuscitation and transport directly to an experienced trauma centre significantly lowers mortality and morbidity.<sup>15</sup> This is of relevance in areas where a tiered referral system often results in delayed arrival of children with severe traumatic brain injuries at the centres adequately equipped to manage them.

#### TREATMENT OF SEVERE TBI

Guidelines for the management of adult TBI have been published and paediatric guidelines are currently being developed.<sup>16</sup> It is important to see the management of these patients as being a continuum from scene to surgery.

#### Emergency resuscitation

The primary approach, which begins at the accident scene, is based on the ABC of resuscitation as advocated by ATLS. Once a patent airway has been secured, position the patient flat to optimise perfusion of the brain in case the patient is shocked. Maintain the head in the midline position in case of spinal instability and also to prevent compression of the neck veins.

Ensure that the patient is breathing adequately and in children without facial injuries bag and mask ventilation can be accomplished without extension of the neck using the "sniffing the morning air" position. An open airway and adequate ventilation will correct hypercarbia and the addition of supplemental oxygen will avoid hypoxia. Children who arrive at hospital hypoxic have a worse outcome.

Finally, paying attention to the circulation to reverse systemic hypotension if present is of paramount importance. Isotonic or hypertonic fluids should always be used for resuscitation and never hypotonic fluids such as dextrose and water, which tend to exacerbate the cerebral oedema with its consequent fluids shifts.

Associated spinal injury is rare in childhood compared to in adults with concomitant head injuries and, while careful synchronised logroll movement of the patient is important, spine boards are better avoided in those under the age of two years as at this stage the large calvarium is forced into flexion by the spine board and this can compromise the airway and the spine. Following resuscitation, the child should be transferred to a centre equipped for paediatric neurosurgery.

#### Emergency room care

A complete physical examination of the unclothed child is carried out. A primary survey is conducted looking for evidence of polytrauma to the chest, abdomen or skeleton. A large venous

access line and urinary catheter is secured.

An endotracheal tube will be required in virtually all children with a GCS of less than 8 or those in shock.<sup>17</sup> The use of agents such as short-acting benzodiazepines, for example midazolam 0.2 mg/kg IVI to facilitate a smooth intubation is preferred to avoid the rise in intracranial pressure that occurs with intubation and vocal cord spasm. Once the endotracheal tube is in place, the aim is for a pAO<sub>2</sub> > 100 mmHg and a paCO<sub>2</sub> of around 30 mmHg.

Once the child is haemodynamically stable, appropriate radiological studies are indicated. Plain cervical spine radiographs are obtained, although it must be remembered that up to 60% of spine injuries in children may be "SCIWORA" (spinal cord injury without radiographic abnormality).

A non-contrast CT of the head is crucial. The period where the child leaves the emergency room to go to the radiology department is often one of least monitoring and a time of high risk for secondary injury and one should use portable monitors.

If CT scan reveals an intracranial haematoma, urgent neurosurgical intervention is of paramount importance. The concept of the *golden hour* exemplifies the principle that if removal of haematoma causing mass effect is delayed, secondary brain injury occurs due to increased ICP.

#### Intensive care unit

Once the child is in the ICU, correction of any acidosis, hypotension, hypoxia and hypercarbia is a priority. Abnormal clotting studies are common in children and should be corrected as soon as possible. Hyponatraemia usually relates to overproduction of anti-diuretic hormone (SIADH) or to overjudicious intravenous fluid administration. Fluid balance and electrolytes must be monitored carefully.

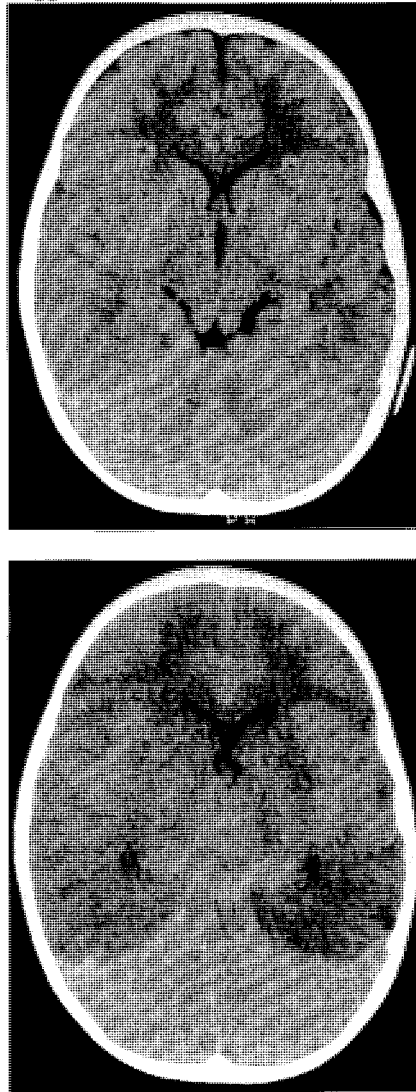
Cerebral perfusion pressure (CPP) is defined as mean arterial pressure (MAP) minus the ICP.

$$\text{CPP} = \text{MAP} - \text{ICP}$$

The essence of treating severe TBI entails controlling ICP and maintaining MAP. Intracranial hypertension ultimately reduces both regional and

global cerebral perfusion and causes secondary ischaemia. This leads to further brain swelling and/or herniation, the consequences of which are clearly seen in Figure 6.

**Figure 6: Admission CT following closed head injury (a) and follow up 5 days later after development of refractory cerebral swelling (b). The dark appearance of the hemispheres suggests severe ischaemic injury**



It is helpful to approach the control of raised ICP in a step-wise fashion, starting with the simplest strategies (Figure 7).

#### 1. Head position

Maintaining the head in a neutral position and elevating the head of the bed to 30° can facilitate adequate cerebral venous drainage, and possibly CSF drainage. Jugular venous compression must be avoided.

#### 2. Sedation and paralysis

Sedation and paralysis are often used in the treatment of severe head injured patients as they reduce the noxious stimuli of routine ICU care, which may increase ICP. Short-acting benzodiazepines such as midazolam are generally recommended for intermittent or continuous use.

#### 3. Controlled ventilation

Hyperventilation has long been used as a treatment for intracranial hypertension, based on the known cerebral vasoconstriction response to hypocapnea, but this has recently been rejected as a therapeutic intervention since it was found to *worsen* outcome in adults with severe traumatic brain injuries.<sup>16</sup> The current recommendation is to aim for low normal paCO<sub>2</sub> and avoid hyperventilation.

#### 4. Osmotic diuretics

The delivery of osmotic diuretics to the brain can be an effective way to lower intracranial pressure. It has been assumed that the mode of action is withdrawal of extracellular water from the normal brain, resulting in a decreased brain volume. The exact action is not clear and may even include reduced CSF production from the intracranial space.

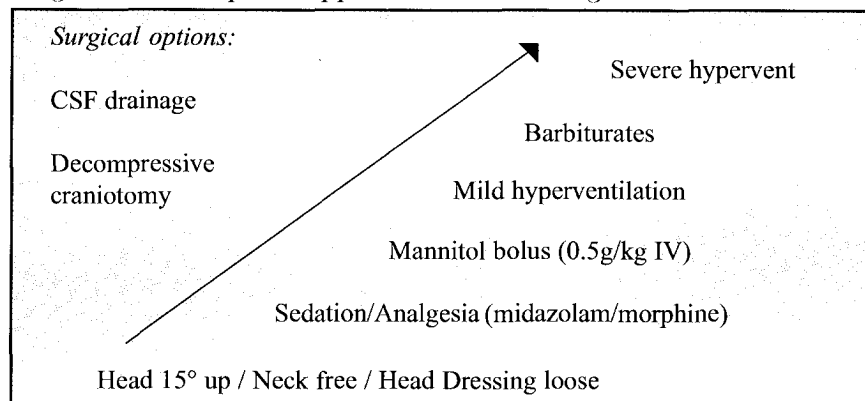
The most frequently used agent is mannitol given in doses of 0.25-1 g/kg intravenously. We generally reserve its use for patients with mass lesions and clinical evidence of raised intracranial pressure who are awaiting neurosurgical intervention in whom a recent randomised prospective trial has shown a definite benefit.<sup>18</sup>

Care should be taken to avoid the dehydration and hypotension often associated with its use. Some question the use of mannitol in children because of its tendency to increase cerebral blood flow in a number of patients with injury, thus worsening cerebral swelling.

#### 5. Mean arterial pressure

Contemporary management of infants or children with severe traumatic brain injuries includes the maintenance of adequate perfusion, which can usually be achieved with normotension or mild systemic hypertension. Because of the uniqueness of children and age and size variation in cerebral perfusion pressure, the optimal mean arterial pressure in

Figure 7: A stepwise approach to the management of raised ICP



therapists, occupational therapists and neurobehavioural psychologists as early as possible in the patient's rehabilitation.

## CONCLUSION

Head trauma remains a leading cause of death and disability, which is also devastating to the family. Although the primary traumatic brain injury is not amenable to treatment, except through prevention, conventional management is focused on reducing effects of the secondary physiological events and secondary insults that occur after the injury.

It is clear that the poor outcomes observed are best avoided by preventing the initial insult or the secondary insults that typically occur following traumatic brain injuries. Continued aggressive intervention aimed at strategies to prevent or minimise the mechanisms of injury will become increasingly important.

Please refer to the CPD questionnaire on page 61.

## References

1. Semple PL, Bass DH, Peter JC. Severe Head Injury in Children; a preventable but forgotten epidemic. *S Afr Med J* 1998; 88: 440-444.
2. Shapiro K, Smith LP. Special considerations for the pediatric age group. In: Cooper PR (ed). *Head Injury* 3rd edition. Williams and Wilkins: Baltimore, 1995.
3. Adelson PD, Kochanek PM. Head injury in children. *J Child Neurol* 1998; 13: 2-15.
4. Jennet B, Teasdale G. Assessment of Coma and Impaired Consciousness. *Lancet* 1974; 2: 81-84.
5. Raimondi AJ, Hirschauer J. Head Injury in the Infant and Toddler; Coma scoring and outcome scale. *Child's Brain* 1984; 11: 12-35.
6. Ommaya AK, Goldsmith W, Thibault L. Biomechanics and neuropathology of adult and pediatric head injury. *Br J Neurosurg* 2002; 16: 220-242.
7. Pigula FA, Wald SL, Shackford SR, Vane DW. The Effect of Hypotension and Hypoxia on Children with Severe Head Injuries. *J Ped Surg* 1993; 28: 310-316.
8. Duhaime AC, Christian CW, Rorke LB, Zimmerman RA. Nonaccidental Head Injury in Infants - The "Shaken Baby Syndrome". *New Engl J Med* 1998; 338: 1822-1829.
9. Geddes JF, Vowles GH, Hackshaw AK, Nickols CD, Scott IS, Whitwell HL. Neuropathology of inflicted head injury in children II. Microscopic brain injury in infants. *Brain* 2001; 124: 1299-1306.
10. Merservy CJ, Towbin R, McLaurin RL, Myers PA, Ball W. Radiographic Characteristics of Skull Fractures Resulting from Child Abuse. *AJR* 1987; 149: 173-175.
11. Peter JC, Domingo Z. Subacute traumatic haematomas of the posterior fossa: A clinico-pathological entity of the 5- to 10-year-old-child. *Child's Nervous System* 1990; 6: 135-138.
12. Van den Hoeve CM, van der Merwe DJ. Management of depressed skull fractures. *J Neurosurg* 1989; 71: 186-190.
13. Beattie TF. Minor Head Injury. *Arch Dis Childhood* 1997; 77: 82-85.
14. Humphreys RP. Complications of Pediatric Head Injury. *Pediatr Neurosurg* 1991; 17: 274-278.
15. Johnson DL, Krishnamurthy S. Severe head-injured children to a Pediatric Trauma Centre. *Pediatr Neurosurg* 1996; 25: 309-314.
16. The Guidelines may be accessed on the Internet at the URL [http://www.braintrauma.org]
17. Bruce DA, Trumble ER, Steers J. Pathophysiology and Treatment of severe head injuries in children. In: Choux M et al. (eds) *Pediatric Neurosurgery* 1st edition, Churchill Livingstone: London, 1999.
18. Cruz J, Minoja G, Okuchi K. Improving clinical outcomes from acute subdural hematomas with the emergency preoperative administration of high doses of mannitol: a randomized trial. *Neurosurg* 2001; 49: 864-871.
19. Clifton GL, Miller ER, Choi SC, Levin HS et al. Lack of effect of induction of hypothermia after acute brain injury. *New Engl J Med* 2001; 344: 556-563.
20. Laurent-Vannier A, Brugel DG, De Agostini M. Rehabilitation of brain-injured children. *Ch Nerv Syst* 2000; 16: 760-764.

children is difficult to determine. Management must be tailored to the individual patient so as not to damage an already compromised brain.

## 6. Anticonvulsants

Seizures can increase ICP and secondary injury therefore it is recommended that anticonvulsants be administered prophylactically to patients with severe head injuries who have raised ICP. They should also be considered if there is a penetrating or parenchymal injury as the incidence of post-traumatic seizures is much higher in penetrating injuries. Usual agents are phenobarbitone or phenytoin 18 mg/kg loading dose and 3-5 mg/kg maintenance dose daily.

## 7. Analgesia

This is essential in the management of trauma and may encompass the use of Paracetamol or opiates such as tilidine (Valoron) or morphine. This has often been rejected in head injuries due to its emetic and pupil-constricting effects but is probably safe if given by infusion in the ICU.

## 8. Neuroprotective agents

Thiopentone has long been advocated to reduce cerebral metabolic demands so that an ischaemic level of bloodflow may be tolerated for longer periods. Barbiturate use in children remains somewhat controversial with deleterious effects on haemodynamic stability due to myocardial depression.

Unfortunately none of the newer agents that have shown great promise in laboratory animals has had clinical efficacy. Recent attention has focused on hypothermia as early reports have suggested that outcome may be

improved by cooling patients, but a recent prospective trial failed to find any benefit in adults.<sup>19</sup> What is clear is that hyperthermia (greater than 38°C) is detrimental post injury, and should be treated.

## 9. Intracranial pressure monitoring

Monitoring ICP aids in the early detection of intracranial mass lesions and in the rational use of therapies to control intracranial pressure. Systems in use include subdural transducers and ventricular catheters which have the advantage of allowing therapeutic removal of CSF. Guidelines for ICP monitoring in children are still being developed.

The definitive strategy for reducing ICP is to remove any mass lesions but there is increasing interest in the use of decompressive craniotomy in selected cases.

## DISCUSSION

It has been consistently noted that very young children seem to suffer more long-term sequelae to traumatic brain injury than toddlers and older children. All these contribute to the morbidity following a significant brain injury.<sup>20</sup>

Post traumatic epilepsy is a common sequel especially to penetrating cerebral injury and can present a management challenge particularly in young infants. There are a myriad of physical and cognitive disabilities, especially neurobehavioural and adaptive behaviour changes that the clinician will encounter in the child's convalescence.

What is clear is that the best possible care requires a multidisciplinary approach with involvement of physio-