

# Anaesthesia for oesophageal atresia with or without tracheo-oesophageal atresia

Palesa Motshabi

Principal Specialist, Charlotte Mxeke Johannesburg Academic Hospital and Department of Anaesthesia, University of the Witwatersrand, Johannesburg, South Africa

Corresponding author, email: [motshabi.chakane@gmail.com](mailto:motshabi.chakane@gmail.com)

## Abstract:

Oesophageal atresia, with or without tracheo-oesophageal fistula, is one of the most challenging conditions with which the anaesthesiologist has to deal during the perioperative period. The patients are usually in their first few days of life, and might be premature with inherent airway problems. This is then compounded by airway and respiratory complications presented by this lesion. These patients often present with a multitude of other congenital anomalies that may have a bearing on the oxygen cascade. With improvements in antibiotic choices, prenatal diagnosis, neonatal intensive care and surgical options, outcomes in this patient group have improved immensely. This manuscript serves to highlight the anaesthetic considerations of these conditions, while also examining recent developments in this patient population.

**Keywords:** anaesthetic management, oesophageal atresia, tracheo-oesophageal fistula

## Introduction

A fistula, a Latin word meaning "a tube", is an abnormal connection between two tubes or surfaces. A tracheo-oesophageal fistula (TOF), is a congenital anomaly that is characterised by a connection to the trachea, with or without a disruption of the oesophagus. An isolated disruption of the oesophagus is termed oesophageal atresia.

## Embryology

The trachea and the oesophagus develop during the third week of embryonic life from the primitive foregut. In the fourth week of life, considerable communication between the respiratory and the gastrointestinal tracts is normal (large TOF).<sup>1</sup> Three theories aim to explain how the separation of the foregut into a ventral portion (laryngotracheal tube) and dorsal portion (oesophagus) develops.<sup>2</sup> These scientific theories have been tested mainly on animals, and not on human embryos, for ethical reasons. The fact that these studies cannot be performed on human embryos means that there are many unanswered questions as the animal studies are not a true representation of what would occur in the human embryo.

The first theory postulates that the respiratory foregut buds off from the ventral foregut, continues to grow longitudinally, and with programmed cell death, separates from the foregut.<sup>2,3</sup> Failure of normal rapid longitudinal growth of the tracheal tissue away from the foregut then results in the compensatory overgrowth of undivided foregut buds originating directly from the foregut, therefore creating fistulous connections. The failure of active separation also causes rearrangement of the cranial foregut, resulting in a blind-ending atretic proximal pouch.

The second theory of development alludes to the separation of the trachea and oesophagus by invagination and fusion of the lateral walls.<sup>2,3</sup> Failure of this separation then leads to a distal

fistula, with the proximal blind-ending loop being a result of the rearrangement caudally. A parallel theory suggests the formation of a septum originating from the lung buds.

The third theory combines the first two theories, suggesting the development of three folds, the laryngeal, pharyngo-oesophageal and tracheo-oesophageal folds.<sup>2,3</sup> Pairing of the laryngeal and pharyngo-oesophageal folds define the tracheo-oesophageal space with approximation of these folds, and separates the trachea from the oesophagus. A separate fold in the dorsal portion creates a boundary between the pharynx and the oesophagus. This theory suggests that the oesophagus develops separately and becomes malformed and atretic by a separate unknown mechanism, and suggests an outgrowth from the trachea which forms the fistula.<sup>2,3</sup> The mechanism behind this is not known either.

A new school of thought postulates teratogenicity as an alternative cause to the widely accepted genetic cause to these abnormalities.<sup>3,4</sup> Drugs such as Adriamycin® were associated with teratogenicity in studies by Diez-Pardo et al.<sup>3,4</sup> Unfortunately, most of the research is performed on animal models as it is unethical to replicate on human embryos. Therefore, it is difficult to understand exactly what the causative factors of TOF and oesophageal atresia are in humans without the use of human embryos. There is an intertwined relationship between multi-system congenital abnormalities with TOF and oesophageal atresia being associated with several other anomalies, the most common being cardiac lesions. An understanding of the neonatal developmental physiology and embryology, as depicted in Streeter's horizons, gives guidance to the relationship of the timelines of these anomalies.<sup>1</sup>

## Pathophysiology

The oesophagus in TOF is abnormal, with abnormal motility and peristalsis, resulting in an intrinsically higher resting pressure

and a reduced closing pressure of the cardiac sphincter.<sup>5</sup> An abnormality of innervation as a contributing factor may not be distinguishable from vagal nerve trauma in the perioperative period. The trachea may have a deficiency of cartilage rings in the vicinity of the fistula and an increase in the transverse muscle in the posterior wall.<sup>5</sup> These abnormalities explain the usual postoperative complications commonly encountered, such as oesophageal stenosis, gastro-oesophageal fistula and recurrent fistulae.

## Epidemiology

The incidence of TOF and oesophageal atresia is 1 in every 3 000–5 000 births.<sup>5–8</sup> There is a 30–50% incidence of associated vertebral defects, anal atresia, trachea-oesophageal fistula with oesophageal atresia, cardiac defects, and renal and limb (VACTERL) anomalies in neonates with TOF and oesophageal atresia.<sup>5–8</sup> Cardiac lesions occur in 20% of patients, while vertebral, anal, renal and limb anomalies occur in 17%, 12%, 16% and 10%, respectively.<sup>5–7</sup> An association with prematurity affects their prognosis.<sup>5–7</sup> The most common form, with an incidence of 85%, involves a blind proximal oesophageal loop with a distal TOF (Figure 1). This is represented as type C in the Gross, and type IIIB in the Vogt, classifications (Table 1). Long gap oesophageal atresia (type A) is the most complicated to correct, necessitating a multitude of operations.

Associations with midline anomalies (palatolaryngotracheal and urogenital), Holt-Oram syndrome, Di George syndrome, polysplenia, and Pierre Robin syndrome have been described with lower incidences.<sup>6–8</sup> Other associations may include CHARGE (coloboma, heart defect and atresia choanae) Potter's and Shisis syndromes, and chromosomal anomalies, such as Trisomy 21 and 18, and 13q deletion.<sup>5</sup>

## Classification

The TOF and oesophageal atresia anomalies have been classified in terms of their anatomical variations and for diagnostic, surgical planning and prognostic purposes. The anatomical classification was pioneered by Vogt in 1929, and modified by Ladd and Gross in 1944 and 1953, respectively. The Vogt and Gross classifications are still used extensively. They describe the morphology of the lesions without any bearing on prognosis. Kluth also modified the original Vogt classification in a publication entitled *Atlas of Esophageal Atresia* in 1967.<sup>5</sup>

**Table 1:** The Gross and Vogt classifications<sup>5–7</sup>

Gross	Description	Vogt
-	Oesophageal agenesis	Type I
Type A	Proximal and distal bud (mid-oesophagus missing)	Type II
Type B	Distal bud with proximal trachea-oesophageal fistula	Type III, A
Type C	Proximal atresia with a fistula to the distal bud (85–90% of cases)	B
Type D	Both proximal and distal buds connected to the trachea by fistulae	C
Type E (H type)	The two segments of the oesophagus communicating	-

## Clinical features

The neonate presents during the postnatal period with coughing, gagging, choking and respiratory distress.<sup>5–8</sup> The respiratory symptoms may be confused with those due to hyaline membrane disease or pneumonia. The neonate may also present with cyanosis owing to repeated episodes of aspiration. Because of an association with congenital heart disease, specifically Tetralogy of Fallot, double outlet right ventricle, tricuspid atresia, atrial septal defect and ventricular septal defect, the diagnosis may be delayed as cyanosis may be mistaken for that of cardiac disease.<sup>9</sup> There is an increased incidence of prematurity in TOF and oesophageal atresia neonates; up to 18% in a retrospective review by Andropoulos et al, and 40% in an audit by Knottenbelt et al.<sup>10,11</sup>

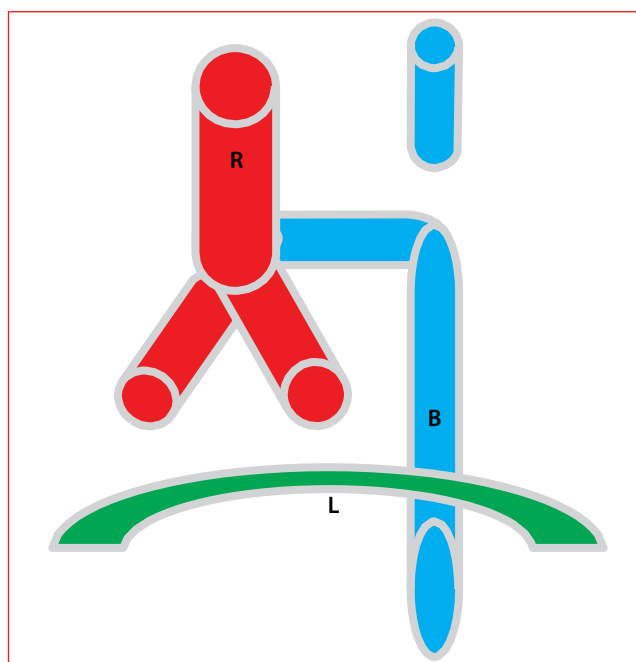
## Diagnosis

### Prenatal

Excessive amniotic fluid seen on a prenatal foetal ultrasound is suspicious of gastrointestinal obstruction, but not specific.<sup>5–9</sup> A high index of suspicion is necessary.

### Postnatal

An initial prenatal assessment with suspicion of TOF facilitates earlier diagnosis. Failure to pass a nasogastric tube beyond 7 cm with the suspicion of TOF is the first sign.<sup>6,8,12</sup> A curled up nasogastric tube in the upper thoracic area on a chest X-ray is part confirmatory (Figure 2). A complete oesophageal atresia with no fistula will present with a scaphoid abdomen with no gastric bubble on X-ray.<sup>7</sup> ATOF presents with an inflated enlarged gastric bubble on X-ray.<sup>12</sup> Contrast studies are not necessary as the risk of chemical pneumonitis is high.



**Figure 1:** Type C (Waterston classification)/IIIB (Spitz classification) TOF  
B: oesophagus, L: Diaphragm, R: tracheobronchus

**Table 2:** Waterston classification<sup>15-17</sup>

Category	Weight and co-morbidities	Surgical timing	Survival rates (%)
A	2 500 g	Immediate surgery	100
B	1 800–2 500 g pneumonia and congenital anomalies	Short-term delay, plus stabilisation	95
C	1 800 g severe pneumonia and congenital anomalies	Staged repair	35

### Surgical management

Rigid bronchoscopy performed under anaesthesia prior to thoracotomy yields important information about the position and size of the fistula.<sup>5,9,10</sup> Rigid bronchoscopy can be used for the delivery of a Fogarty catheter in the fistula with inflation of the balloon for isolation (Figure 3).<sup>9,10,13</sup> Thoracotomy is the approach commonly performed in many centres. This involves an extrapleural dissection of the posterior mediastinum.<sup>5,14</sup> The fistula is ligated and a primary oesophageal anastomosis performed. The anastomosis is performed at a later stage in a staged procedure.

Using the transpleural approach, the lateral position and relative one lung ventilation because of retraction of the lung on the operation side, complicates ventilation in an already compromised neonate.<sup>14</sup> A complete understanding of the pulmonary and cardiac anatomy is necessary prior to surgery as this determines the side of thoracotomy or thoracoscopy. An absent or poorly developed right lung, a right-sided aortic arch and dextrocardia necessitate a review of strategy.

Timing of surgery is assessed using the Waterston or Spitz risk stratification systems. The Waterston classification uses the neonate's weight, severity of pneumonia and other congenital anomalies to assess survival rates.<sup>15-17</sup> Waterston risk categories have a survival rate of 99% for group A, 95% for group B and 71% for group C (Table 2). The Spitz classification uses birth weight and co-morbidities as prognostic tools (Table 3).

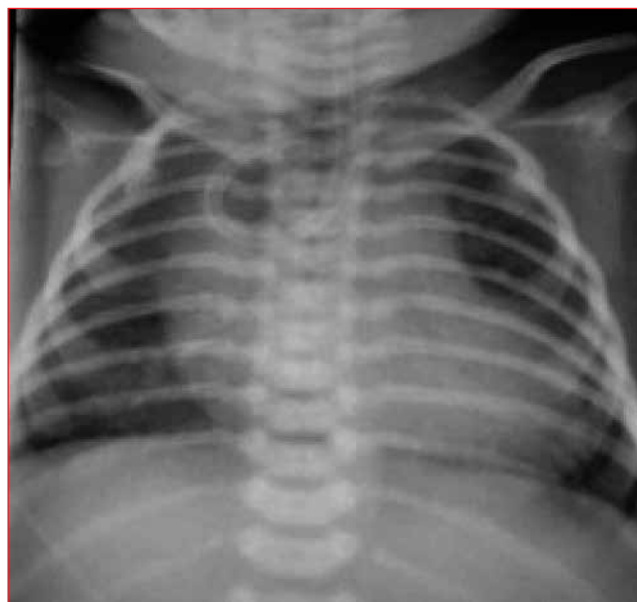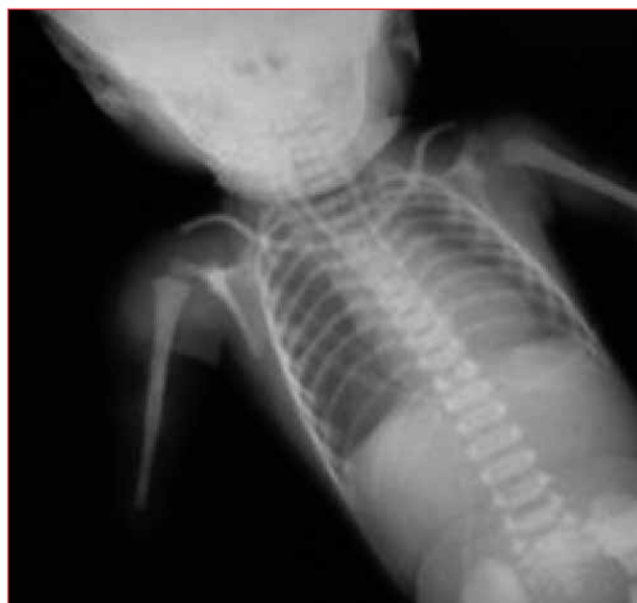With advances in technology, thoracoscopic repairs are slowly increasing in many centres. Thoracoscopic repair of a TOF or oesophageal atresia poses an added challenge to the anaesthesiologist's ventilation management by adding gas insufflations to lung collapse.<sup>18-24</sup>

Long gap oesophageal atresia often cannot be corrected in the first operation and necessitates staged operations. It is sometimes necessary to use alternative tissue transplants to close the gap.<sup>25,26</sup> The different tissue types have a multitude of complications, ranging from perforations to malignancies.<sup>25,26</sup> Extensive research is continuing in an attempt to find the best method of repair for long gap oesophageal atresia.<sup>25,26</sup>

The paediatric surgical fraternity continues to explore ways of correcting long gap oesophageal atresia, with the most suitable tissue being the oesophagus itself.<sup>27-31</sup> Of these procedures, the most frequently described is the Kimura technique which involves externalisation of the oesophagus and traction to encourage growth with primary closure at a later stage.<sup>29,32</sup>

**Table 3:** Spitz classification<sup>57</sup>

Group	Birthweight	Cardiac abnormalities	Survival (%)
I	> 1 500 g	Without	98
II	< 1 500 g	Or	80
III	< 1 500 g	With	50

**Figure 2:** Nasogastric tube in proximal pouch**Figure 3:** VACTERL (vertebral defects, anal atresia, trachea-oesophageal fistula with oesophageal atresia, cardiac defects, and renal and limb) association airway management

Adhesions with continuous elongations are the main problem with this procedure. In 2000, Dessanti et al modified the Kimura technique by using a Gore-Tex® material wrapped around the oesophagus to prevent adhesions in a 1 kg infant with success.<sup>33</sup> The Collis-Nissen procedure, although still using the oesophagus, involves a gastric pull through into the chest, which presents with similar problems as a gastric transplant.<sup>27</sup> The Collis-Nissen technique was modified and adapted to long gap oesophageal atresia by Aoyama in 1985, with reportedly successful results.<sup>27</sup> Foker described a procedure whereby the

oesophagus was tractioned via the transthoracic route.<sup>28,30</sup> A combination of the Kimura and Foker procedures has been used with some success.<sup>29</sup> In 2006, Vogel et al reported a case of growth facilitation of long gap oesophageal atresia using hydrostatic stretch.<sup>34</sup> After 14 days, they achieved a pouch overlap, but only performed a primary reconstruction after 65 days owing to delays in optimising the patient's cardiovascular condition.<sup>34</sup>

Tissue engineering has been described as far back as 1983 when Fukushima et al used a tissue-engineered oesophagus in animal studies.<sup>35</sup> This tissue yielded more fibrous tissue than neo-oesophageal tissue. In 1998, Takimoto et al engineered a neo-oesophagus that showed stratified flattened epithelium, longitudinal and circular muscle layer and glands.<sup>35</sup> This had been generated on non-absorbable tissue. In the same year, Shinhar et al experimented with using an absorbable material as a skeleton.

Other investigators later discovered some nerve innervations, but others reported a higher rate of leakage in the neo-oesophagus.<sup>35</sup> With constantly improving stem cell science, oesophageal reconstruction could soon be performed successfully in humans as the science of biopolymers also improves.

## Anaesthetic approach

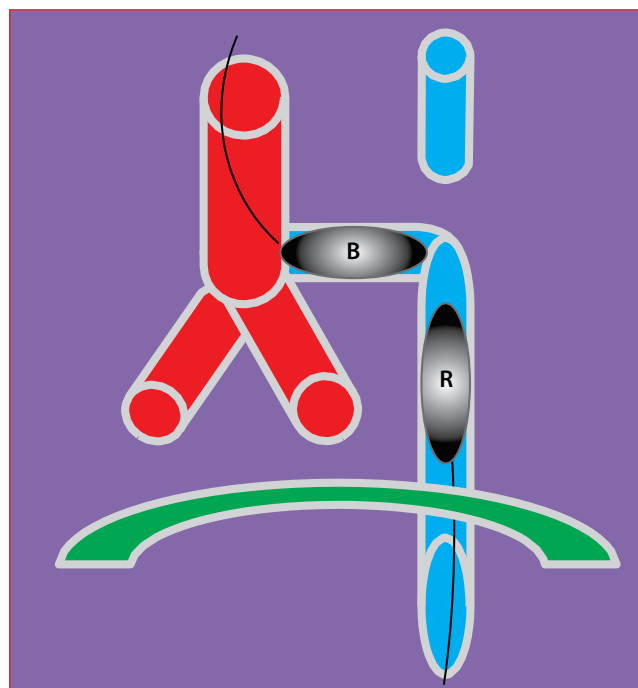
### Preoperative preparation

Haematological and biochemical profiles are obtained early and abnormalities of electrolytes and acid base corrected. Rehydration should be commenced promptly. Blood should be typed and screened prior to taking the patient to theatre. Empirical antibiotics are recommended because of an increased risk of aspiration.<sup>6,15</sup> Hypoglycaemia is common and should be treated. A neonate who is in respiratory distress should be treated as the situation necessitates, although ideally it is better not to ventilate preoperatively.<sup>10</sup> A pump suction is applied to the proximal pouch to remove saliva and secretions. Nursing in a supine semi-upright or lateral position prevents aspiration.<sup>9</sup> A decision to perform a gastrostomy can be made at this point if ventilation is problematic.<sup>5,9,13</sup> The gastrostomy tube, if inserted, could be used in the postoperative period for feeding during the staged procedure.

A cardiac examination, including an echocardiogram, is necessary to assist with risk stratification and for surgical access planning.<sup>9,16,17</sup> Renal ultrasound and skeletal radiology are performed to exclude TOF as part of VACTERL (Figure 3). Genetic mapping and counselling should be undertaken in suspicious cases.<sup>5</sup>

Airway management and ventilatory strategies are the most important part of this procedure. The goal is to avoid the insufflation of fresh gas into the fistula, and subsequently into the stomach, resulting in massive distention and further impairment of ventilation, resulting in hypoxaemia.

Different ways of airway management have been described and complications to these highlighted. Isolation of the fistula and facilitation of ventilation is paramount in the initial stages of the operation. Failure of isolation could have devastating consequences, including hypoxaemia, and even death.<sup>36</sup> Traditionally, the method of inserting the endotracheal tube (ETT) as deeply towards the carina as possible, with gentle manual ventilation and pulling of the tube back to a point where



**Figure 4:**

B: Fogarty catheter with inflated balloon antegrade, R: Fogarty catheter with inflated balloon retrograde

both lungs are ventilated, is the one commonly used.<sup>8,36,37</sup> The difficulty with this method is that the tube could migrate during positioning and ventilation of the fistula may need to be re-initiated. With the Murphy eye of the ETT, it is sometimes quite difficult to achieve fistula isolation. An ETT without a Murphy eye should be used where possible. Alternatively, a Murphy eye should be kept on the right side of the ETT during placement. A case report by Alabbad et al highlights the pitfalls of this type of manoeuvre, where the tube migrated into the fistula after positioning with fatal consequences.<sup>36</sup> In another case report by Llewellyn and Reed, another complication was reported, with suturing in of the tube while ligating the fistula because of the proximity of the tube to the fistula.<sup>37</sup> The blind occlusion of the fistula, as shown in a report by Hack and Raj, might miss a second undiagnosed fistula with untoward complications.<sup>38</sup> This shows the imperfection of this method, which only uses auscultation to confirm the position of the tube.

An alternative method of airway management is by exclusion of the fistula during the bronchoscopy stage of the operation. A catheter can be inserted prograde into the fistula and the balloon inflated to occlude the fistula ("B" in Figure 4).<sup>10,11</sup> Alternatively, the catheter could be inserted through the gastrostomy incision retrograde to occlude the fistula distally ("R" in Figure 4).<sup>10</sup> This method may be superior to the initial described method as it involves some form of visualisation of the fistula. This does not mean a second fistula could not be missed though.

Intubation of an anaesthetised, spontaneously breathing neonate has been described as another form of airway management.<sup>39</sup> Hoskings and Motshabi reported success with this method in a neonate with a carinal fistula, in whom a gastrostomy was not performed preoperatively to decompress the stomach.<sup>39</sup> This method requires a good pain management strategy that enables the neonate to breath spontaneously without the respiratory depression of opioids and the use of muscle relaxants until the

fistula is occluded or ligated.<sup>7,8,10</sup> Regional anaesthesia, in the form of an epidural or caudal, offers good conditions for such a manoeuvre. In a retrospective review by Andropoulos et al, 93% of their patients had muscle relaxation prior to intubation, with ventilation difficulties in 21% mainly due to TOF ventilation.<sup>10</sup>

Flexible bronchoscopes, which have been in use since the 1960s, seem not to have been widely adopted in the neonatal anaesthesia field.<sup>40-42</sup> The smallest fibre-optic bronchoscope, with a diameter of 1.8 mm, could fit into a 2.5 mm ETT and be used to confirm positioning of the tube. The Olympus® BF N-20 and PF 27-M are two such ultrathin flexible bronchoscopes on the market. The disadvantage of these bronchoscopes is that they lack a suction port to aspirate secretions from the airway.<sup>40-42</sup>

The consequences of hypoxaemia can be devastating to the immature brain. Extracorporeal circulation, which is often used in the repair of congenital tracheal resection, can be used in situations where oxygenation is not adequate despite other manoeuvres, and in conditions such as a TOF with congenital heart lesions with decreased pulmonary blood flow or left lung hypoplasia.<sup>43,44</sup>

## Monitoring

The role of end-tidal CO<sub>2</sub> monitoring for airway obstruction during surgery or retraction is extremely useful. ETT and airway problems could still be missed, even with CO<sub>2</sub> monitoring.<sup>36,37</sup> A central line assists with accessing prolonged fluid management, parenteral feeding where necessary, a portal to give inotropes or prostaglandins in ductus arteriosus-dependent physiology and a measure of filling pressure. Invasive arterial cannulae in patients with cardiac anomalies will help with beat-to-beat blood pressure monitoring and serial samples for blood gas analysis, particularly in a patient with intractable vomiting and metabolic derangements.

## The physiology of lateral decubitus position

V/Q matching in children, unlike that in adults, favours the healthy lung "up".<sup>14</sup> This is particularly important if there is aspiration and pneumonia in both lungs. Because they have a soft rib cage of a small size, the dependent lung does not have increased blood flow which is promoted by hydrostatic or gravitational pressure difference between the two lungs.<sup>14</sup>

Functional residual capacity becomes closer to residual volume and airway closure is likely, even with tidal ventilation.<sup>14</sup> An inherent increase in oxygen consumption predisposes these infants to hypoxia. Therefore, there is an increased risk of desaturation in the decubitus position.<sup>14</sup>

This concept is important in the choice of surgical method, especially in a patient whose pulmonary function is already borderline. Thoracoscopic surgery, although superior in view of its lesser postoperative complications, such as pain and neuromuscular disorders, necessitates the use of gas insufflation and lung collapse via a transpleural approach.<sup>18-24</sup> This method can complicate ventilation in the already difficult-to-ventilate patient. The extrapleural approach would then seem to be a better option in such cases.

## Pain management

Choices of pain management in a spontaneously breathing infant should be patient specific. Narcotics can be administered safely in a patient whose fistula is either isolated with an inflated catheter balloon or the side of an inflated ETT balloon.

Regional analgesia, by way of a caudal, epidural or paravertebral block allows for spontaneous ventilation, especially in cases in which fistula isolation is difficult.<sup>14</sup> The insertion of a catheter through the caudal needle to a measured length at T6/T7 blindly or with confirmation by ultrasound, provides excellent surgical conditions for continued spontaneous ventilation.<sup>7</sup>

Non-narcotic analgesics should be added as part of a multimodal analgesic regimen as regional anaesthesia may not cover some visceral areas.<sup>14</sup> In an prospective audit that examined patient characteristics, analgesia details and ventilation details, Palmer et al<sup>45</sup> found a significantly higher proportion of neonates who were preterm had low birthweight and co-morbidities, needed longer ventilation times and more top-up analgesia with morphine, when compared to those born at 36 weeks with a birthweight of 2.5 kg or more.<sup>46</sup>

## Complications

### Early

Neonates who are left intubated remain at a risk of disruption of suture lines and fistula recurrence.<sup>10,11</sup> Those who are transferred to a postoperative facility extubated have a risk of re-intubation which may be emergent, leading to trauma to the tissues and resultant anastomosis leaks.<sup>10,11</sup> An anastomotic leak was found in 29% of cases in one study.<sup>16</sup> Patients without cardiac anomalies have a mortality rate of less than 1.5% (Table 3). Pneumonia and ventilatory problems may persist. Wound sepsis, hypoxia complications, gastric perforation and missed fistulae have been described in some studies. An approach to treating a missed fistula was described by Roman et al using a fibrin glue, Tissucol®, through a rigid bronchoscope with a success rate of 85%.<sup>47</sup> An argon plasma coagulation probe can be used to fulgurate the residual fistula orifice when obliteration of the fistula with tissue glue has failed.<sup>48</sup> Lung collapse, cord palsy, phrenic palsy, chylothorax and pleural fistula formation have also been documented, although with lower incidences.<sup>11</sup>

### Late

Gastro-oesophageal reflux is the most common late complication, occurring in up to 50% of cases.<sup>49-55</sup> Tracheomalacia and oesophageal stricture are also common.<sup>49-55</sup> Chronic respiratory and otolaryngological complications may also persist into adulthood.<sup>49-56</sup>

Musculoskeletal abnormalities, such as scoliosis, in those who had a thoracotomy, as compared to a thoracoscopic procedure, may also occur.<sup>49-55</sup> Chronic pain may be observed in some cases if pain management is inadequate.<sup>10</sup>

Gastric and colonic interposition have their unique set of complications. These include a risk of cancer development, delayed gastric emptying resulting from vagotomy, increased gastric emptying and failure to thrive due to loss of gastric reservoir capacity.<sup>25,26</sup> Interestingly, despite all the concerns

regarding these complications, Burgos et al published results of a follow-up of 96 patients, and discovered only one death due to carcinoma of the native oesophagus in patients with a colon interposition graft.<sup>26</sup>

## Prognosis

Prediction of morbidity and mortality, based on preoperative factors, is based on the Waterston and Spitz classification (Tables 2 and 3).<sup>57</sup> The Waterston classification (A, B and C), an earlier classification to that made by Spitz which was proposed in 1990 (groups I, II and III), uses birthweight, pneumonia and congenital anomalies, and classifies neonates according to three groups. According to the Waterston classification, survival rates are as follows: group A: 100%, group B: 95% and group C: 35%. According to the Spitz classification, low-birthweight premature neonates with cardiac anomalies have a 50% survival rate, and may need to undergo a staged procedure, as discussed previously.<sup>57</sup> There is a 98% survival rate in group I with a birthweight of more than 1 500 g without major cardiac disease, that of 80% in group II with a birthweight of less than 1 500 g or major cardiac disease, and 50% in group III with a birthweight of less than 1 500 g and major cardiac disease (Table 3). These results seem to be reproducible when studies are taken into consideration that report on long-term outcomes, and which distinctly show that the presence of co-morbidities increases the risk of morbidity and mortality, including ventilation days, number of procedures performed, ICU and hospital stay.<sup>49-56</sup> Long gap oesophageal atresia is an independent factor in the difficulty of correction, and also necessitates multiple procedures to be performed. Of the patients with cardiac lesions, Diaz et al found that those with ductal-dependant cardiac disease were at increased risk of morbidity and mortality, compared to those without it.<sup>17</sup>

A study by Niramis et al that compared outcomes using the Waterston and Spitz classifications with patients operated on between 2003 and 2010, demonstrated superiority over the Spitz classification in the risk stratification and prognostication of patients.<sup>57</sup> A group of 132 neonates was included into the study. The Waterston classification showed no statistical difference between groups A and B, and a significant statistical difference was seen between groups I and II and III when using the Spitz classification.<sup>57</sup> It is suggested that advances in clinical medicine in the fields of prenatal medicine, neonatal intensive care, anaesthesiology and paediatric surgery should be credited for the improved survival in group B using the Waterston classification, probably rendering this classification inaccurate in modern medicine.<sup>57</sup>

## Conclusion

It is particularly important to understand the cardiorespiratory pathophysiology in TOF and oesophageal atresia. Without these considerations during surgery and anaesthesia, severe morbidity and mortality could ensue. Commonly, this group of patients has a multitude of cardiac lesions, including cyanotic cardiac anomalies. Misinterpretation and mismanagement of cardiac anomalies could lead to the patient reverting to foetal circulation with sudden cardiorespiratory arrest. The right-sided aortic arch, right lung and right pulmonary artery disease are contraindications to right-sided thoracotomy. It is important to understand the physiology of left lateral positioning in neonates and children as it differs from that in adults, and if not managed

properly, could complicate the already difficult ventilation situation. The anaesthesiologist should always remember the considerations of anaesthesia for a (preterm) neonate, including temperature and glucose management. The use of fibre-optic bronchoscopes to confirm positioning and relation to the fistulae could be of great help in avoiding some of the complications. More work needs to be carried out on encouraging this modality of ETT placement in neonates in the operating theatre. The use of extracorporeal circulation, as used in congenital tracheal stenosis, should be considered in extreme cases of anticipated and real ventilation difficulty.

## References

1. Keane JE, Lock JE, Fyler CD. NADAS' Pediatric Cardiology. 2nd ed.. Elsevier Inc.; 2013.
2. Pinheiro PFM, Silva ACS, Pereira RM. Current knowledge on esophageal atresia. *World J Gastroenterol.* 2012;18(28):3662-72.10.3748/wjg.v18.i28.3662
3. Loannides AS, Copp AJ. Embryology of oesophageal atresia. *Semin Pediatr Surg.* 2009;18:2-11.10.1053/j.sempedsurg.2008.10.002
4. El-Gohary Y, Gittes GK, Tovar JA. Congenital anomalies of the esophagus. *Semin Pediatr Surg.* 2010;19:186-93.10.1053/j.sempedsurg.2010.03.009
5. Spitz L. Oesophageal atresia. *Orphanet J Rare Dis.* 2007;2:24.10.1186/1750-1172-2-24
6. Al-Rawi O, Booker PD. Oesophageal atresia and tracheo-oesophageal fistula. *Continuing Educ Anaesth Crit Care Pain.* 2007;7(1):15-19.
7. Gayle JA, Gomez SL. Anaesthetic considerations for the neonate with tracheoesophageal fistula. *Middle East J Anesthesiol.* 2008;19(6):1241-54.
8. Burns LS, Crone RK. Anesthetic considerations in the patient with tracheoesophageal fistula. *J Am Assoc Nurse Anesth* 1984;589-94.
9. Holcomb GW III, Rothenberg SS, et al. Thoracoscopic repair of esophageal atresia and tracheoesophageal fistula. *Ann. Surg.* 2005;242(3):422-30.
10. Andropoulos DB, Rowe RW, et al. Anaesthetic and surgical airway management during tracheo-oesophageal fistula repair. *Pediatr Anesth.* 1998;8:313-9.10.1046/j.1460-9592.1998.00734.x
11. Knottenbelt G, Costi D, et al. An audit of anesthetic management and complications of tracheo-esophageal fistula and esophageal atresia repair. *Pediatr Anesth.* 2012;22:268-74.10.1111/pan.2012.22.issue-3
12. Lerman, Cote, Steward. *Manual of pediatric anaesthesia.* 6th ed. Churchill Livingstone Elsevier. 2010: 350-6.
13. Rothenberg SS. Thoracoscopic repair of tracheoesophageal fistula in newborns. *J Pediatr Surg.* 2002;37(6):869-72.10.1053/jpsu.2002.32891
14. Hammer GB. Pediatric thoracic anesthesia. *Anesthesiology Clin N Am.* 2002;20(1):153-80.10.1016/S0889-8537(03)00059-2.
15. Niramis R, Tangkhuanbut P, et al. Clinical outcomes of esophageal atresia: comparison between the Waterston and the Spitz classifications. *Ann Acad Med.* 2013;42(6):297-300.
16. Clark DC. Esophageal Atresia and Tracheoesophageal Fistula. *Am Fam Physician.* 1999 15; 59(4): 910-6.
17. Diaz LK, Akpek EA, et al. Tracheoesophageal fistula and associated congenital heart disease: implications for anesthetic management and survival. *Pediatr Anesth.* 2005;15:862-9.10.1111/pan.2005.15.issue-10
18. Hiraifar M, Shojaeian R, et al. Thoracoscopic esophageal atresia repair made easy. An applicable trick. *J Pediatr Surg.* 2013;48:685-8.10.1016/j.jpedsurg.2012.12.019
19. Rothenberg SS. Thoracoscopic repair of esophageal atresia and trachea-esophageal fistula. *J Pediatr Surg.* 2005;14:2-7.
20. Van der Zee DC, Bax KMA. Thoracoscopic treatment of esophageal atresia with distal fistula and of tracheomalacia. *Seminars in Pediatric Surgery.* 2007;16:224-30.10.1053/j.sempedsurg.2007.06.003
21. Van der Zee DC, Vieira-Travassos D, et al. Thoracoscopic elongation of the esophagus in long gap esophageal atresia. *J Pediatr Surg.* 2007;42:1785-8.10.1016/j.jpedsurg.2007.06.023
22. Rice-Townsend S, Ramamoorthy C, Dutta S. Thoracoscopic repair of a type D esophageal atresia in a newborn with complex congenital heart disease. *J Pediatr Surg.* 2007;42:1616-9.10.1016/j.jpedsurg.2007.05.013
23. Huang J, Tao J, et al. Thoracoscopic repair of oesophageal atresia: experience of 33 patients from two tertiary referral centres. *J Pediatr Surg.* 2012;47:2224-7.10.1016/j.jpedsurg.2012.09.011

24. Bax KMA, van der Zee DC. Feasibility of thoracoscopic repair of esophageal atresia with distal fistula. *J Pediatr Surg.* 2002;37(2):192–6.10.1053/jpsu.2002.30253
25. Gupta DK, Sharma S. Esophageal atresia: the total care in a high-risk population. *Sem Pediatr Surg.* 2008;17:236–43.10.1053/j.sempedsurg.2008.07.003
26. Burgos L, Barrena S, et al. Colonic interposition for esophageal replacement in children remains a good choice: 33 year median follow-up of 65 patients. *J Pediatr Surg.* 2010;45:341–5.10.1016/j.jpedsurg.2009.10.065
27. Nakahara Y, Aoyama K, et al. Modified Collis-Nissen procedure for long gap pure esophageal atresia. *J Pediatr Surg.* 2012;47:462–6.10.1016/j.jpedsurg.2011.08.001
28. Foker EJ, Tara C, et al. A flexible approach to achieve a true primary repair for all infants with esophageal atresia. *Sem Pediatr Surg.* 2005;14:8–15.10.1053/j.sempedsurg.2004.10.021
29. Till H, Rolle U, et al. Combination of spit fistula advancement and external traction for primary repair of long-gap esophageal fistula. *Ann Thorac Surg.* 2008;86:1969–71.10.1016/j.athoracsur.2008.05.056
30. Foker JE, Krosch TCK, et al. Long-gap esophageal atresia treated by growth induction: the biological potential and early follow-up results. *Sem Pediatr Surg.* 2009;18:23–9.10.1053/j.sempedsurg.2008.10.005
31. Petrosyan M, Estrada J, et al. Esophageal atresia/tracheoesophageal fistula in very low-birth-weight neonates: improved outcomes with staged repair. *J Pediatr Surg.* 2009;44:2278–81.10.1016/j.jpedsurg.2009.07.047
32. Tamburri N, Boglione M, Martinez-Ferro M. Extrathoracic esophageal elongation (Kimura's technique): a feasible option for the treatment of patients with complex esophageal atresia. *J Pediatr Surg.* 2009;44:2420–5.10.1016/j.jpedsurg.2009.07.037
33. Dessanti A, Caccia G, et al. Use of Gore-Tex surgical membrane to minimize surgical adhesions in multistaged extrathoracic esophageal elongation for esophageal atresia. *J Pediatr Surg.* 2003;35(4):610–2[TQ11].
34. Vogel AM, Yang EY, Fishman SJ. Hydrostatic stretch-induced growth facilitating primary anastomosis in long-gap esophageal atresia. *J Pediatr Surg.* 2006;41:1170–2.10.1016/j.jpedsurg.2006.01.076
35. Zani A, Pierro A, et al. Tissue engineering: an option for esophageal replacement? *Sem Pediatr Surg.* 2009;18:57–62.10.1053/j.sempedsurg.2008.10.011
36. Alabbad SI, Shaw K, et al. The pitfalls of endotracheal intubation beyond the fistula in babies with type C esophageal atresia. *Sem Pediatr Surg.* 2009;18:116–8.10.1053/j.sempedsurg.2009.02.011
37. Llewellyn R, Reed A. Unusual complication in a neonate following tracheoesophageal fistula repair. *Pediatr Anesth.* 2011;21:1163–72.
38. Hack H, Raj N. An unknown second tracheoesophageal fistula: a rare cause of postoperative respiratory failure. *Pediatr Anesth.* 2006;16:479–83.10.1111/pan.2006.16.issue-4
39. Hoskin C, Motshabi-Chakane P. Thoracotomy in a spontaneously breathing neonate undergoing tracheo-oesophageal fistula repair. *S Afr J Anaesth Analg.* 2013;19(6):321–322.
40. Roberts S, Thornington RE. Paediatric bronchoscopy. *Continuing Educ Anaesth Crit Care Pain.* 2005;5:41–44.10.1093/bjaceaccp/mki015
41. Fan LL, Sparks LM, et al. Applications of an ultrathin flexible bronchoscope for neonatal and pediatric airway problems. *CHEST.* 1986;89(5):673–6.10.1378/chest.89.5.673
42. De Blic J, Delacourt C, Scheinmann P. Ultrathin flexible bronchoscopy in neonatal intensive care units. *Arch Dis Child.* 1991;66:1383–5.10.1136/adc.66.12.1383
43. Liston DE, Richards MJ. Venoarterial Extracorporeal Membrane Oxygenation (VA ECMO) to facilitate combined pneumonectomy and tracheoesophageal fistula repair. *J Cardiothorac Vasc Anesth.* Forthcoming 2013.
44. Goldman AP, Macrae DJ, et al. Extracorporeal membrane oxygenation as a bridge to definitive tracheal surgery in children. *J Pediatr.* 1996;128:386–8.10.1016/S0022-3476(96)70289-5
45. Palmer GM, Thalayasingam P, et al. Audit of extrapleural local anaesthetic infusion in neonates following repair of trachea-esophageal atresia via thoracotomy. *Anaesth Intensive Care.* 2012;40(1):172–80.
46. Wu ET, Wang CC, et al. Concomitant slide tracheoplasty and cardiac operation for congenital tracheal stenosis associated with VACTERL. *Ann Thorac Surg.* 2013;96(4):1492–5.10.1016/j.athoracsur.2013.04.122
47. Roman CGS, Barrios JE, et al. Long-term assessment of the treatment of recurrent tracheoesophageal fistula with fibrin glue associated with diathermy. *J Pediatr Surg.* 2006;41:1870–3.10.1016/j.jpedsurg.2006.06.014
48. Nardo GD, Oliva S, et al. Video: argon plasma coagulator in a 2-month-old child with tracheoesophageal fistula. *Surg Endosc.* 2012;26:2678–80.10.1007/s00464-012-2214-7
49. Rintala RJ, Sistone S, Pakarinen MP. Outcome of esophageal atresia beyond childhood. *Semin Pediatr Surg.* 2009;18:50–6.10.1053/j.sempedsurg.2008.10.010
50. Holland AJA, O Ron, et al. Surgical outcomes of oesophageal atresia without fistula for 24 years at a single institution. *J Pediatr Surg.* 2009; 44:1928–32.10.1016/j.jpedsurg.2009.02.008
51. Koivusalo AI, Pakarinen MP, Rintala RJ. Modern outcomes of oesophageal atresia: single centre experience over the last twenty years. *J Pediatr Surg.* 2013;48:297–303.10.1016/j.jpedsurg.2012.11.007
52. Burford JM, Dassinger MS, et al. Repair of esophageal atresia with tracheoesophageal fistula via thoracotomy: a contemporary series. *Am J Surg.* 2011;202:203–6.10.1016/j.amjsurg.2010.09.035
53. Burjonrappa S, Thiboutot E, et al. Type A esophageal atresia: a critical review of management strategies at a single center. *J Pediatr Surg.* 2011;46:65–71.
54. Kaur H, Kaur R, et al. Unusual complication in a neonate following tracheo-oesophageal fistula repair. *Pediatr Anesth.* 2011;21:1163–72.
55. Lal DR, Oldman KT. Recurrent tracheoesophageal fistula. *Eur J Pediatr Surg.* 2013;23(3):214–8.
56. Bresci G, Sacco R. Pulmonary or otolaryngologic extraesophageal manifestations in patients with gastroesophageal reflux disease. *World J Gastrointest Endosc.* 2011;2(2):47–9.
57. Spitz L, Kiely EM, et al. Oesophageal atresia: at-risk groups for the 1990s. *J Pediatr Surg.* 1994;29:723–5.10.1016/0022-3468(94)90354-9

Received: 01-10-2013

Accepted: 07-07-2014