

# Torsion of a wandering spleen

Charles P Carapinha, MB BCh, MRCS

Jerome A Loveland, MB BCh, FCS (SA), Cert Paed Surg

Department of Paediatric Surgery, University of the Witwatersrand, Johannesburg

Corresponding author: C P Carapinha (ccarapinha@hotmail.com)

Torsion of a wandering spleen is a rare and difficult diagnosis in the paediatric population, with death a possible outcome. In this paper we present our experience of a single case and discuss the embryology and management thereof.

The pathogenesis of a wandering spleen is related to embryological absence or acquired laxity of the supporting splenic ligaments, particularly the gastrosplenic and splenorenal ligaments. Wandering spleen may present in varying forms, from an incidentally detected radiological mass to an asymptomatic, mobile intra-abdominal mass or, as in our case, the more sinister presentation of severe pain secondary to torsion.

## Case report

A 9-year-old girl presented to casualty with a 3-day history of peri-umbilical pain progressing to generalised abdominal pain, associated with nausea and non-bile-stained vomitus. There was no significant past medical or surgical history. On general examination, tachycardia and dry mucous membranes were noted with no pyrexia or generalised lymphadenopathy. The abdomen was mildly distended with generalised tenderness and guarding but no peritonism. On peri-umbilical palpation there was an impression of an intra-abdominal mass. Haematological and serological investigations were undertaken, and the results are set out in Table I. A plain erect chest radiograph demonstrated distended loops of small bowel extending infradiaphragmatically on the left with no air/fluid levels or evidence of pneumoperitoneum (Fig. 1). The findings on abdominal ultrasonography were reported to be normal. After admission to the paediatric surgical ward the patient's condition deteriorated, with the development of bile-stained vomitus and peri-umbilical peritonism, necessitating surgical intervention.

A midline laparotomy revealed the cause of the abdominal pain. A 720-degree torsion of a wandering spleen on its vascular pedicle was found (Fig. 2). The spleen was enlarged, firm and

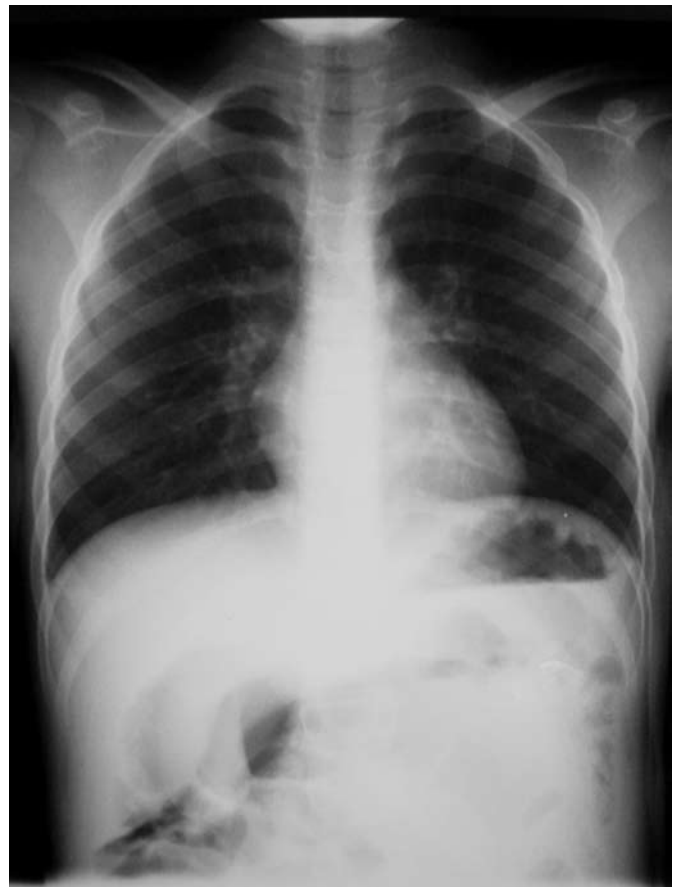

Fig. 1. Erect chest radiograph indicating dilated loops of small bowel extending infradiaphragmatically on the left where the spleen is normally located.

TABLE I. HAEMATOLOGICAL AND SEROLOGICAL RESULTS

Haematology	
White cell count	20.9×10 <sup>9</sup> /l
Haemoglobin	11.3 g/dl
Platelet count	465×10 <sup>9</sup> /l
Serology	
C-reactive protein	251 mg/l
Amylase	54 U/l

congested with diffuse patches of necrosis. Of interest was the fact that the vascular pedicle of the wandering spleen arose from the left gastro-epiploic artery and vein on the greater curvature of the stomach, with no evidence of a splenic artery or vein. No other splenic supporting ligaments were present. No improvement was noted on detorsion of the vascular pedicle, and a splenectomy was performed. The spleen measured 120×90×55 mm and weighed 250 g. Histological examination of the organ identified significant haemorrhagic congestion associated with diffuse haemorrhagic necrosis, with no neoplasm or infiltrate.

There were no postoperative complications. On discharge the patient received pneumococcal vaccination.

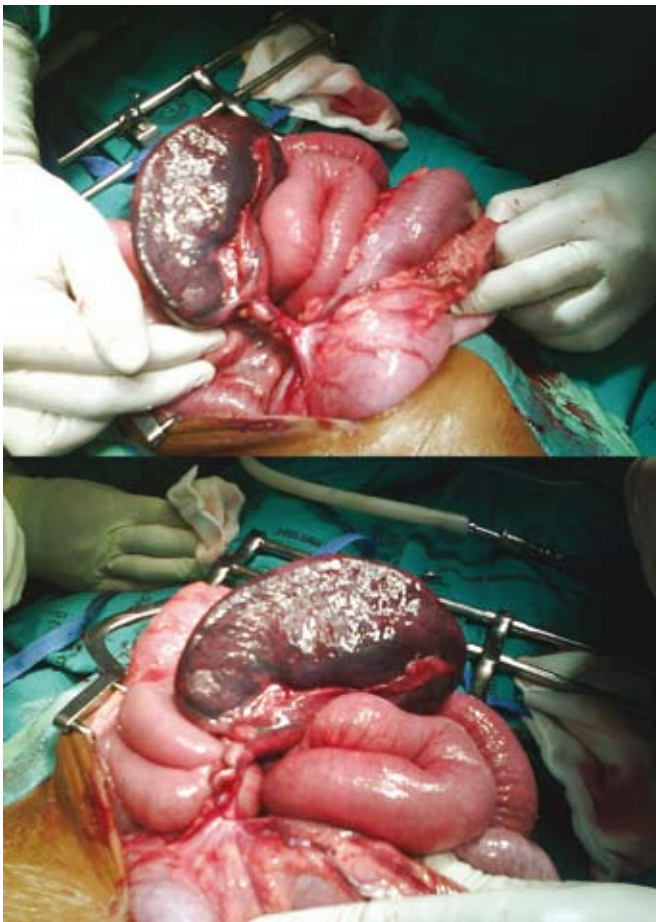


Fig. 2. Torsion of a wandering spleen.

## Discussion

The first description of a wandering spleen is attributed to Von Horne,<sup>1</sup> in 1667, as an autopsy finding on an adult. Two pathological mechanisms to account for the clinical entity of a wandering spleen have been described. Either embryological absence or acquired laxity of the splenic supporting ligaments allows for increased mobility of the spleen and hence a greater propensity to torsion. There is no clear explanation for failure in development of the supporting ligaments. The acquired variant is more common in females after the age of 10 years,<sup>2</sup> and it has been suggested that pregnancy contributes to the laxity of supporting ligaments by the direct effect of oestrogen.<sup>3</sup>

Briefly, the spleen develops during the 5th week of gestation within the dorsal mesogastrium. The developing spleen divides this into an anterior portion which will develop into the gastrosplenic ligament, and a posterior portion which will develop into the splenorenal ligament (Fig. 3). As the stomach rotates in a clockwise direction the posterior portion of the dorsal mesogastrium (splenorenal ligament) fuses with the peritoneum overlying the developing left kidney, attaching the spleen to the posterior abdominal wall. Normally the spleen is supplied and drained by the splenic artery and vein, respectively, which traverse the splenorenal ligament towards the hilum of the spleen. In our case the spleen received its arterial supply and venous drainage from the left gastro-epiploic artery and vein on the greater curvature of the stomach with complete absence of the splenorenal ligament, splenic artery and splenic vein. This in itself is a very unusual anatomical arrangement, and to our knowledge this is the first time that such an anatomical variant has been described in a case of wandering spleen. With only the gastrosplenic

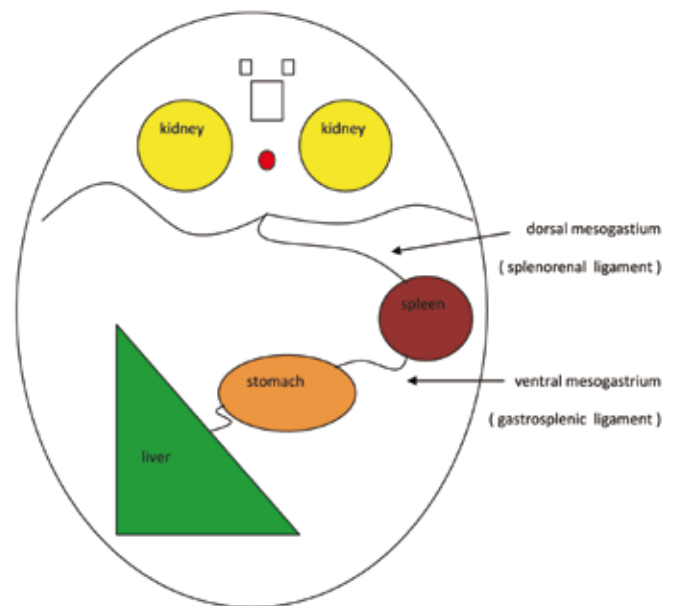


Fig. 3. Relationship of the splenic ligaments during embryological development.

ligament present the spleen underwent torsion, first occluding the venous drainage and subsequently the arterial supply as evidenced by the histological findings of significant haemorrhagic congestion and diffuse haemorrhagic necrosis.

Wandering spleen has many forms of presentation; however, in a recent review of 238 patients,<sup>4</sup> 73% and 67% of cases presented with abdominal pain or an abdominal mass, respectively. Diagnosis is predominantly radiological, with colour-flow ultrasonography being the initial investigation of choice. Computed tomography and liver-spleen radionuclide scans are other adjuncts if the diagnosis is in question.

Surgery is the mainstay of treatment, as shown by a 65% complication rate noted for cases treated conservatively.<sup>5</sup> Splenopexy and splenectomy are the two options available. Splenopexy is the process of fixing the mobile spleen in its natural position, either with a synthetic mesh or by creating a retroperitoneal pouch and placing the spleen within it. This can be achieved either as a laparoscopic or as an open procedure. Splenectomy is reserved for cases in which the spleen is deemed to be non-salvageable, as in our case. The greatest risk of splenectomy in children is the development of overwhelming post-splenectomy sepsis, necessitating appropriate vaccination and antibiotic prophylaxis.

## Conclusion

Wandering spleen is a rare and difficult diagnosis in the paediatric population. Surgery forms the mainstay of treatment, and is well tolerated in children.

## References

1. Correnson H. *Quelques Recherches sur les Displacements de Larate*. Paris: A Parent, 1876.
2. Dawson JH, Roberts NG. Management of the wandering spleen. *Aust N Z J Surg* 1994; 64(6): 441-444.
3. Robinson AP. Wandering spleen: case report and review. *Mt Sinai J Med* 1988; 55(5): 428-434.
4. Soleimani M, Mehrabi A, Kashfi A, Fonouni H, Büchler MA, Kraus TW. Surgical treatment of patients with wandering spleen: Report of six cases with a review of the literature. *Surg Today* 2007; 37(3): 261-269.
5. Buehner B, Baker MS. The wandering spleen. *Surg Gynecol Obstet* 1992; 175(4): 373-387.