

# Aggressive desmoid fibromatosis: First case in a Rwandan child

A Kanyamuhunga,<sup>1,2</sup> MD, MMed; N McCall,<sup>1,2</sup> MD, MPH; L Tuyisenge,<sup>1,2</sup> MD, MMed; C Mumena,<sup>3</sup> DDS, MDent; D C Stefan,<sup>4</sup> MD, PhD

<sup>1</sup> Department of Paediatrics and Child Health, Kigali University Teaching Hospital, Kigali, Rwanda

<sup>2</sup> Faculty of Medicine, National University of Rwanda, Butare, Rwanda

<sup>3</sup> Kigali Health Institute, Kigali, Rwanda

<sup>4</sup> Department of Paediatrics and Child Health, Faculty of Health Sciences, Stellenbosch University, South Africa

Corresponding author: D C Stefan (cs@sun.ac.za)

Desmoid tumours are a rare group of locally aggressive, non-malignant tumours of fibroblastic origin that can result in significant morbidity due to local invasion. Facial involvement in children with aggressive fibromatosis is uncommon. We present the case of a 14-month-old Rwandan child with an aggressive desmoid tumour involving the left mid-facial region. The patient presented with severe stertor due to massive nasal obstruction. After intensive supportive care the diagnosis was confirmed histopathologically. Treatment consisted of eight courses of chemotherapy with vincristine, actinomycin-D and cyclophosphamide, followed by surgical removal of the remaining mass. The outcome was impressive and encouraging.

S Afr J CH 2013;7(3):117-118. DOI:10.7196/SAJCH.593



Desmoid tumours are a rare group of locally aggressive, non-malignant tumours of fibroblastic origin that can result in significant morbidity due to local invasion and may even result in a fatal outcome when located around a vital organ. The tumours are known to involve muscle, subcutaneous tissue and neuromuscular structures, with less involvement of the bones.<sup>[1]</sup>

The abdomen remains the most common site of origin of desmoid tumours, which can also occur in extra-abdominal areas.<sup>[2-5]</sup> About one-third of all desmoid tumours are extra-abdominal, with the majority of these occurring in the shoulder girdle or pelvic region. The head and neck are an uncommon site for these lesions, comprising roughly 11-15% of extra-abdominal desmoids.<sup>[6]</sup>

We present the case of a 14-month-old Rwandan child with a desmoid tumour arising on the head in the left mid-face region.

## Case report

A 14-month-old child with stertor due to an obstructive oral mass and a history of progressive facial swelling leading to left nasal obstruction was referred to the Paediatric Department at Kigali University Teaching Hospital, Rwanda. The mass had first been noticed at the corner of the left nostril, progressively involving the side of the face with nasal deviation and complete obstruction over the course of 1 month prior to the patient's arrival in the Department. Examination revealed a firm, non-tender swelling measuring about 12 cm × 5 cm and

involving the upper left gingival and soft palate region with complete obstruction of the left nostril (Fig. 1).

On admission, the patient's general status was marked by facial deformity with mild respiratory distress. The rest of the clinical examination was unremarkable, and there was no lymph node involvement. The patient received immediate supportive care in the form of painkillers and oxygen therapy.

A transcutaneous biopsy of the mass was performed and submitted to the Department of Pathology at Brigham and Women's Hospital, Boston, USA, for histopathological examination. The tumour demonstrated histological features of aggressive fibromatosis. After histopathological confirmation of the disease, the

patient received chemotherapy followed by surgical removal of the remnant mass.

The chemotherapy given included a combination of vincristine, actinomycin-D and cyclophosphamide (VAC). The pre-operative course was given according to the 6 weeks schedule: vincristine 2 mg/m<sup>2</sup> in intravenous (IV) infusion every 2 weeks, actinomycin-D 0.015 mg/kg/d by IV infusion for 5 days every 6 weeks, and cyclophosphamide 200 mg/m<sup>2</sup> during the first course for 7 days and during every course thereafter for 5 days every 6 weeks. The mass had shrunk dramatically after 9 cycles (Fig. 2), and excision of the remaining firm mass was done when the tumour was resectable.

Pathological examination of the resected specimen showed histological features identical to the previous biopsy.

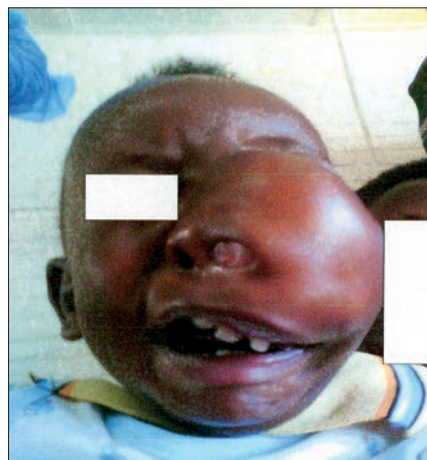

Fig. 1. Desmoid tumour of the face in a 14-month-old child.

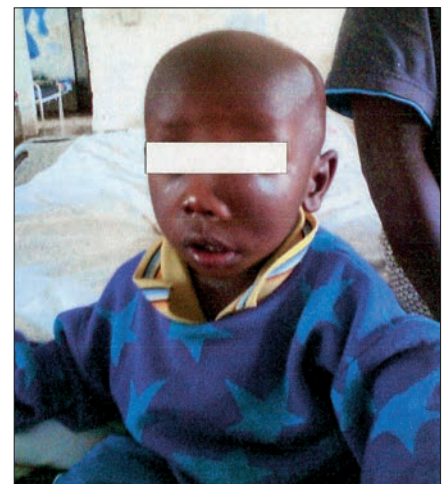

Fig. 2. The response after 9 cycles of chemotherapy.

Postoperatively the patient did well and appears to be free of gross disease after the surgical resection.

## Discussion

Despite being benign tumours, desmoid fibromatosis may aggressively invade adjacent structures. These rare tumours are primarily found in the abdominal wall. Lesions of the head and neck representing a small subset, of which the majority arise in the supraclavicular region. Desmoids of the mid-face, as in our case, are extremely rare. Despite advances in the understanding of these tumours, their natural history is still not clear and the optimal treatment remains debatable.

A range of therapeutic options are available, and choosing the appropriate method for achieving local control depends on the functional and cosmetic outcomes of each method and the associated complications.<sup>[1]</sup> Surgery remains the most favoured option when functionally and cosmetically acceptable. Management with a combination of modalities is useful in irresectable tumours. Radiotherapy may be indicated after margin-positive resection or if irresectable large tumours are present with impending functional problems in older children. Systemic therapies should also be considered when the tumour cannot be resected, especially in cases where radiation toxicity may be also unacceptable.

The current trend is strongly in favour of treating asymptomatic desmoids with observation, reserving treatment for tumours that may pose a threat to vital structures or show continued growth,<sup>[1]</sup> as in our case.

## Conclusion

This is the first case of aggressive desmoid fibromatosis in the mid-face to be described in a Rwandan child. Intensive supportive care on presentation associated with chemotherapy and surgery contributed to the patient's spectacular clinical response.

**Ethics approval.** Ethical approval was obtained from Kigali University Teaching Hospital, Rwanda, and the patient's mother consented to the publication of the photos.

## References

1. Tan YY, Low CK, Chong PY. A case report on aggressive fibromatosis with bone involvement. *Singapore Med J* 1999;40(2):111-112.
2. Enzinger FM, Shiraki M. Musculo-aponeurotic fibromatosis of the shoulder girdle: Analysis of thirty cases followed up for ten or more years. *Cancer* 1967;20(7):1131-1140. [http://dx.doi.org/10.1002/1097-0142(196707)20:7<1131::AID-CNCR2820200716>3.0.CO;2-8]
3. Enzinger FM, Weiss SW. *Soft Tissue Tumors*. St Louis: Mosby, 1983:45-102.
4. Reitamo JJ, Scheinin TM, Hayry P. The desmoid syndrome: New aspects in the cause, pathogenesis and treatment of the desmoid tumor. *Am J Surg* 1986;151(2):230-237. [http://dx.doi.org/10.1016/0002-9610(86)90076-0]
5. Posner MC, Shiu MH, Newsome JL, Hajdu SI, Gaynor JJ, Brennan MF. The desmoid tumor: Not a benign disease. *Arch Surg* 1989;124(2):191-196. [http://dx.doi.org/10.1001/archsurg.1989.01410020061010]
6. Fashing MC, Saleh J, Woods JE. Desmoid tumors of the head and neck. *Am J Surg* 1988;156(4):327-331. [http://dx.doi.org/10.1016/S0002-9610(88)80305-2]

# An unusual case of Milroy disease

N R Schamroth, MB BCH

*Knysna Provincial Hospital, Knysna, Western Cape, South Africa*

*Corresponding author: N R Schamroth (drnscham@gmail.com)*

The interesting case of an infant who presented with congenital lymphoedema with features of Milroy disease is presented. The infant's clinical findings were marked and somewhat atypical. Lymphoscintigraphy demonstrated features consistent with the diagnosis.

*S Afr J CH* 2013;7(3):118-119. DOI:10.7196/SAJCH.639



A 6-month-old female infant was brought to Chris Hani Baragwanath Academic Hospital, Johannesburg, South Africa, in August 2012 by her parents, who came from a rural village in Lesotho. According to her mother, the baby had been born with a 'swollen' body. Her face, upper limbs and right leg were most affected. Although the swelling had decreased over time, it persisted in the upper limbs and right leg. The infant was growing well and had not had any episodes of acute illness, and her milestones were appropriate for her age. Her mother was a primigravida and had had 2 previous miscarriages at 1 month and 3 months, respectively. She reported no prenatal problems and had given birth vaginally at a rural clinic. The baby was born at term with a weight recorded as 3 060 g, and her mother reported no postnatal complications.

Neither of the parents had any illnesses, and there was no history of other family members with a similar condition to that of the child. There was no history of travel to areas endemic for conditions causing lymphoedema.

The baby was active, mobile and curious. Her anthropometry was appropriate for her age and she appeared well with no

dysmorphic features. She had mild peri-orbital oedema and striking, non-pitting brawny oedema of the upper limbs and right leg (Fig. 1). The oedema was marked at the palm and dorsum of the hands and foot with sparing of the distal digits (Fig. 2). The oedema of the arms tapered above the level of the biceps. The oedema of the limbs was non-tender but firm. There was no evidence of lymphadenopathy, ascites or cardiac failure. She had no other dermatological stigmata and had full movement of all her limbs with good power.

The primary diagnosis was congenital lymphoedema, consistent with features of Milroy disease. This diagnosis was confirmed on lymphoscintigraphy, which showed a patent peripheral left lower limb lymphatic system and a lack of tracer migration in the right lower limb and both upper limbs (Fig. 3).

## Discussion

Other differential diagnoses include lymphoedema-distichiasis syndrome, Meige disease, hypotrichosis-lymphoedema-telangiectasia syndrome, Turner syndrome, Noonan syndrome, and lymphoedema with yellow nails/yellow nail syndrome.<sup>[1]</sup>

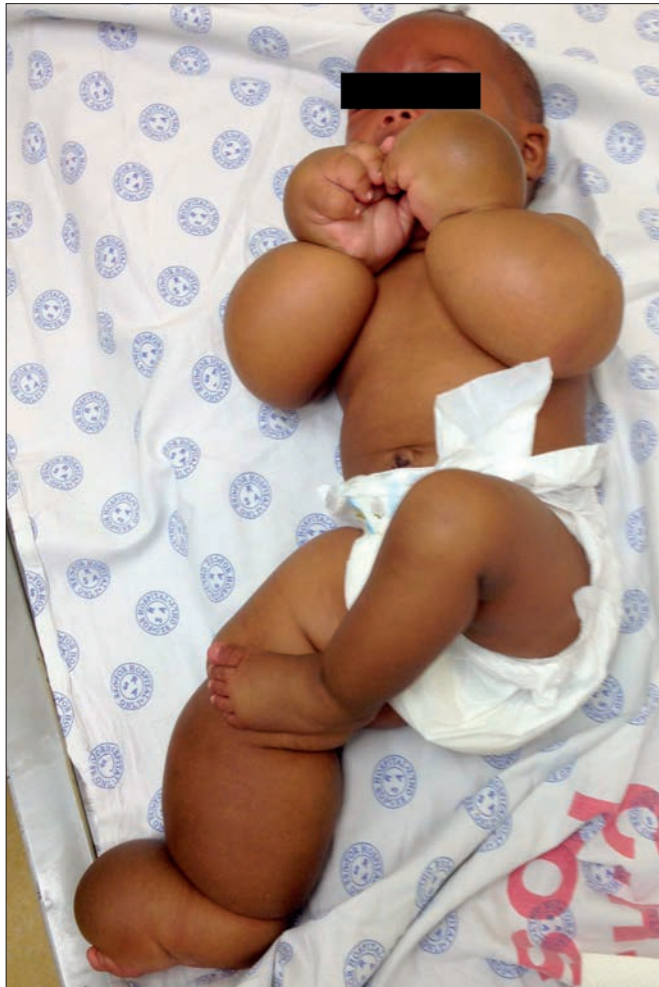

Fig. 1. Infant with lymphoedema of both upper limbs and right lower limb (reproduced with permission from the parents).

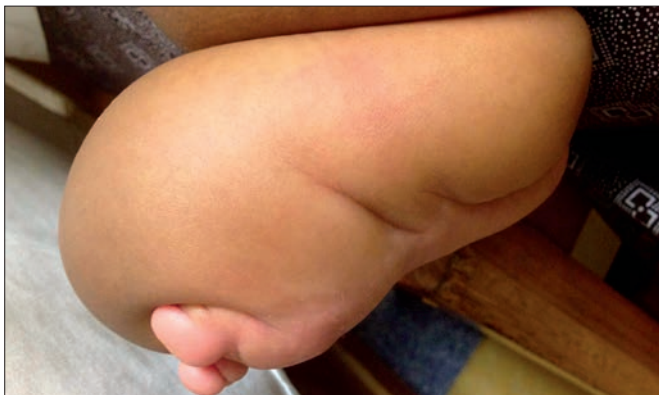

Fig. 2. Right foot, showing typical dorsal oedema (reproduced with permission from the parents).

Milroy disease is a congenital form of primary lymphoedema. It is an autosomal dominant condition inherited with variable expression and

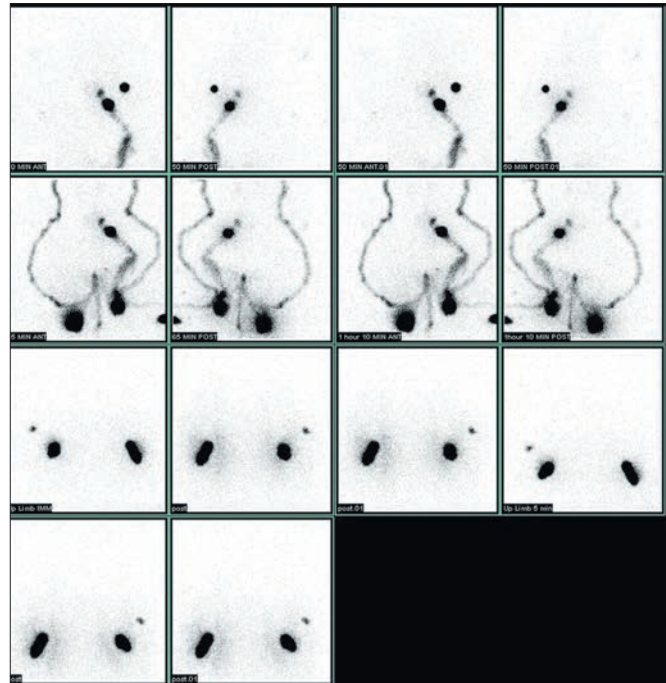


Fig. 3. Lymphoscintigraphy findings in lower and upper limbs, showing a lack of tracer migration in both upper limbs.

reduced penetrance. It is commonly (75% of cases) associated with the vascular endothelial growth factor receptor 3 mutation, which causes abnormal phosphorylation of a tyrosine kinase reception specific for lymphatic vessels.<sup>[2,3]</sup> This causes lymphatic dysfunction leading to lymphoedema.<sup>[4]</sup>

Milroy disease is more common in females than in males. Patients present with firm oedema and the right leg is classically the main limb involved, usually below the level of the knee. The main morbidity is associated with recurrent bouts of cellulitis and lymphangitis. Management is mainly supportive, and no surgical method has achieved lasting success.

This case is unusual, as the infant presented with involvement of three limbs: the right leg above the level of the knee and both arms to the level of the biceps. There was no family history of this condition, and it can therefore be assumed that it is either a sporadic mutation phenomenon or a case of reduced penetrance in a parent.

#### References

1. Brice G, Mansour S, Ostergaard P, Connell F, Jeffrey S, Mortimer P. Milroy disease. Hereditary lymphedema, type I: Milroy congenital lymphedema. In: Pagon RA, Bird TD, Dolan CR, et al, eds. Gene Reviews. Seattle: University of Washington, 1993. <http://www.ncbi.nlm.nih.gov/books/NBK1239/> (accessed 7 August 2013).
2. Connell FC, Ostergaard P, Carver C, et al. Lymphoedema consortium: Analysis of the coding regions of VEGFR3 and VEGFC in Milroy disease and other primary lymphoedemas. *Hum Genet* 2009;124(6):625-631. [<http://dx.doi.org/10.1007%2Fs00439-008-0586-5>]
3. Irrthum A, Karkkainen MJ, Devriendt K, Alitalo K, Vakkula M. Congenital hereditary lymphedema caused by a mutation that inactivates VEGFR3 tyrosine kinase. *Am J Hum Genet* 2000;67(2):295-301. [<http://dx.doi.org/10.1086%2F303019>]
4. Mellor RH, Hubert CE, Stanton AW, et al. Lymphatic dysfunction, not aplasia, underlies Milroy disease. *Microcirculation* 2010;17(4):281-296. [<http://dx.doi.org/10.1111%2Fj.1549-8719.2010.00030.x>]