

# THE HAEMATOLOGY OF HIV INFECTION

David Brittain, FCPATH (Haem), Clin Haem  
Sandton Oncology Centre, Johannesburg

*HIV has become the major health problem in southern Africa. The manifestations of this disease affect every aspect of clinical practice, and the protean symptomatology of HIV infection and AIDS makes a sound approach to the diagnosis of common problems essential. The environment of cost containment within which medical practitioners are required to care for their patients necessitates a thorough understanding of the pathology of these clinical problems in order to facilitate accurate and appropriate diagnosis and therapy.*

*Haematological problems manifest in almost every AIDS patient.<sup>1</sup> The most serious complications are the cytopenias, immune deregulation and haematological malignancies.*

### ANAEMIA

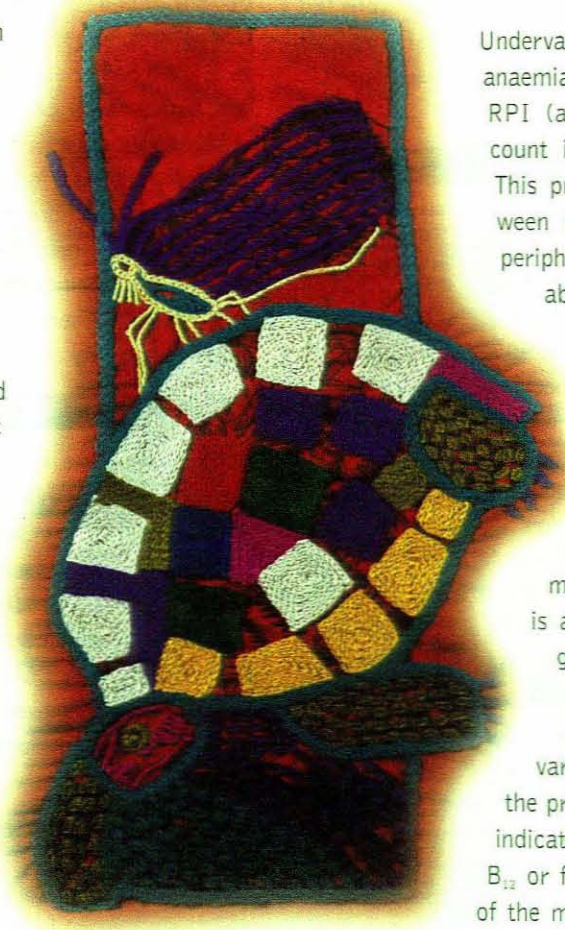
Ninety per cent of patients with AIDS will become anaemic at some point in their illness.<sup>1</sup> Persistent anaemia is predictive of a poor outcome. Therefore, identifying the cause of the anaemia is essential for effective management.

#### Anaemia of chronic disorders

The majority of HIV-related anaemia is anaemia of chronic disease (ACD). This is not usually related to uncontrolled HIV infection *per se* and presents with isolated anaemia. The majority of patients with ACD have an associated chronic inflammatory condition. The hallmarks of ACD are mild to moderate anaemia (haemoglobin (Hb) 8 - 12 g/dl), normocytosis to mild microcytosis (rarely mean corpuscular volume (MCV) < 74 fl), an inadequate reticulocyte response (normal reticulocyte production index (RPI) 1 - 2%), increased iron stores and raised inflammatory markers. This picture should alert the physician to actively exclude an underlying chronic infection such as tuberculosis (TB), MAI, etc.

#### Investigation of Anaemia

Undervalued investigations for diagnosed anaemia include a reticulocyte count and RPI (a correction of the reticulocyte count in proportion to the anaemia). This provides a clear differential between marrow suppression/failure and peripheral loss/consumption, thus enabling the clinician to direct further investigation to either peripheral causes (haemolysis and blood loss) or towards looking for causes of haemopoietic suppression/failure. If the latter is suspected, then a bone marrow aspirate and trephine is an essential part of the investigation, as this provides information regarding the cellularity, relative representation of various haematopoietic lines and the presence of any disorder. This will indicate substrate deficiency (vitamin B<sub>12</sub> or folate). In addition, Pearl's stain of the marrow gives an accurate assessment of iron stores and clearly differentiates between ACD and iron deficiency, without the confusion that may arise with biochemical assessment of serum iron stores and raised ferritin in the context of chronic disease.



## Nutritional anaemia

Haematopoiesis is a sensitive, integrated system of progenitor cells, cytokine support and adequate substrate. Although folate deficiency is rare, low levels of vitamin B<sub>12</sub> are not infrequent. The majority of mild to moderate deficiencies (100 - 200 units) are not clinically significant (assessed using homocysteine levels). The low cost and rare side-effects of intramuscular vitamin B<sub>12</sub> make a trial of therapy an acceptable alternative to extensive investigation. Remember that vitamin B<sub>12</sub> deficiency is often associated with chronic parasitic infections, e.g. giardiasis and amoebiasis, and with ileal dysfunction.

## BONE MARROW SUPPRESSION

Marrow suppression may be due to extensive infiltration by TB, but is more commonly related to cytomegalovirus (CMV) reactivation, uncontrolled HIV infection and malignant infiltration. Numerous studies have failed to show any direct toxic effect of HIV on progenitor cells and yet there is ample evidence of impaired haemopoietic reserve *in vitro* and *in vivo*. This is due largely to a distorted cytokine milieu, infection of bone marrow stromal cells and microvascular endothelial cells (MVECs) by HIV. These cells are universally infected with HIV and have impaired ability to support progenitor cells from non-HIV-infected individuals.<sup>2</sup> Infected individuals have decreased levels of IL4, G-CSF and GM-CSF which contributes to their poor haemopoietic reserve.<sup>3</sup>

## THROMBOCYTOPENIA

Impaired haematopoiesis on the basis of HIV infection tends to cause suppression of thrombopoiesis and granulopoiesis. In addition, these findings are associated with more advanced HIV. In fact a leukocyte count of < 2 is strongly predictive (PPV = 90%) of a CD4 count of less than 200 x 10<sup>6</sup>/l. Thrombocytopenia is a common feature of advanced AIDS and tends to be mild to moderate (platelet count > 80 x 10<sup>9</sup>/l). This is usually associated with anaemia and leucopenia.

Immune thrombocytopenia, on the other hand, is usually an isolated feature of earlier HIV infection (i.e. Hb and white cell count are normal). It is manifested in the early phase of immune deregulation during polyclonal B-cell expansion and polyclonal hyper-gammaglobulinaemia. Its management is similar to that in non-HIV-infected patients, using immunosuppressive doses of steroids. However, the underlying cause is HIV, and once this is controlled the thrombocytopenia usually resolves.

Peripheral platelet destruction is also associated with disseminated intravascular coagulopathy (DIC) and thrombotic thrombocytopenic purpura (TTP). TTP is a feature of advanced AIDS. It presents with the triad of thrombocytopenia, thromboses (often cerebral) and purpuric bleeding. Examination of the peripheral blood smear shows extensive red cell fragmentation. DIC is usually associated with underlying infection or malignancy, especially Kaposi's sarcoma.

Diagnosis is usually made late when there is clinical bleeding, organ failure, thrombocytopenia, prolonged aPTT, low antithrombin level and raised D-dimers. Management is difficult, with a high mortality rate if the underlying precipitant is not controlled.

## LYMPHOMA

Non-Hodgkin's lymphoma is the most common haematological malignancy associated with HIV and has a number of aetiological factors. Low-grade lymphoma presents an increased risk, 14 times that of the general population, but intermediate to high-grade non-Hodgkin's lymphoma is nearly 350 times more common in HIV-infected individuals!<sup>4</sup> The transformation to lymphoma is associated with longer periods of HIV infection, meaning that the risk increases the longer the patient has HIV.

Diffuse large B-cell lymphoma (DLCL) is associated with immune suppression due to other causes, e.g. post-renal transplant, and in this scenario is almost always Epstein-Barr virus (EBV)-associated. However, in HIV, approximately half the patients are EBV-negative, indicating other mechanisms of lymphoma genesis.<sup>5</sup> This may be related to cytokine deregulation and infection of stromal cells/MVECs by HIV. Infected MVECs sustain lymphoma cells in culture better than uninfected stromal cells. This may, at least in part, explain the high incidence of extranodal and primary central nervous system (CNS) lymphomas. In addition, oncogenic viruses such as HHV-8 have been causally linked to primary effusion lymphomas (body cavity-based lymphomas).<sup>5</sup>

Management of HIV-associated lymphomas requires control of the HIV infection. This is a prerequisite as not only is the infection and immune deregulation causally linked to the lymphomas, but the suppressive effects of the virus on haemopoietic reserve and recovery prevent optimal chemotherapy dose intensity. Maintaining dose intensity strongly correlates with outcome.

## CONCLUSION

In conclusion, the investigation and management of the haematological manifestations of HIV require a rational approach and a few simple investigations (start with an FBC, smear and reticulocyte count). The most common problem would be ACD, associated with treatable causes such as TB. Other causes such as myelosuppression related to antiviral drugs, CMV infection, malignant infiltration, etc. can be diagnosed with bone marrow aspiration, serological investigation and by the clinical picture.

## REFERENCES

1. Costello C. Haematological abnormalities in human immunodeficiency virus disease. *J Clin Pathol* 1988; **41**: 711.
2. Wickranasinge SN, Shels S. Bone marrow stromal cell damage in HIV infection. *Clin Lab Haematol* 1993; **15**: 236.
3. Moses A, Nelson J, Bagley GC. The influence of HIV on haematopoiesis. *Blood* 1998; **91**: 1497.
4. Biggar RJ, Rosenberg PS, Cole T, Goedert JJ. Non-Hodgkins lymphoma in AIDS: findings from linking AIDS and cancer registries. *J Acquir Immune Defic Syndr Hum Retroviral* 1993; **14**: A43.
5. Ballerini P, Giandano G, Gong JZ, et al. Multiple genetic lesions in acquired immune deficiency syndrome-related non-Hodgkins lymphoma. *Blood* 1994; **81**: 166.