

## THE IMAGING OF HIV-RELATED BRAIN DISEASE

Jackie Hoare, MB ChB, MRCPsych, FCPsych (SA)

Division of Neuropsychiatry, Department of Psychiatry and Mental Health, University of Cape Town

Advanced HIV disease is strongly associated with an increased occurrence of various neuropsychiatric disorders,<sup>1</sup> and highly active antiretroviral therapy (HAART) is an important aspect of managing these conditions effectively.<sup>2</sup> In addition, there is growing recognition that many HIV-infected individuals will develop neuropsychiatric disorders relatively early in the course of HIV disease, in many cases before CD4 cell counts drop below 500 cells/ $\mu$ l.<sup>3</sup> However, it is not known who in the earlier phases of the disease will go on to develop neurocognitive disorders, or who will respond to treatment.<sup>4,5</sup> New approaches in neuro-imaging have the potential to detect early HIV-associated damage in the brain. Preliminary evidence suggests that the neurotoxic effects of HIV result in damage to white matter tracts in the brain.<sup>6</sup> Once damage is established and related cognitive disorders ensue, the ability of HAART to reverse existing dysfunction is probably limited.<sup>7</sup> Earlier treatment with HAART in at-risk or minimally symptomatic patients may prevent further decline in cognition and delay the course of HIV disease.

### FINDINGS FROM AUTOPSY, CT AND MRI STUDIES

Many individuals infected with HIV eventually present with evidence of neurological involvement, including cognitive deterioration. Autopsy studies of patients with HIV-associated dementia (HAD) demonstrate damage to the deep white matter areas involved in sub-cortical dementia (including the caudate nucleus and basal ganglia).<sup>8</sup> This finding is complemented by results of both computed tomography (CT) and structural magnetic resonance imaging (sMRI), with association between HAD and both diffuse atrophy with ventricular dilatation<sup>9</sup> and deep white matter lesions. Furthermore, a correlation between declining cognitive function and the loss of volume in certain brain structures, including the basal ganglia and caudate nucleus, has also been reported.<sup>10</sup>

Dynamic contrast-enhanced MRI has identified sub-cortical grey and frontal white matter as the principal sites of early metabolic abnormalities in HIV disease.<sup>11</sup> Both increased regional cerebral blood volume and post-contrast enhancement have been reported in the basal ganglia in moderate and advanced HAD, reflecting increased vascularity and blood-brain barrier (BBB) permeability. These findings are consistent with the characteristics of the early neurological deficits, and the known predilection of HIV for the basal ganglia.<sup>12</sup> The degree of neurocognitive impairment in HIV is correlated both with the degree of BBB breakdown in the basal ganglia and with viral load.<sup>13</sup>

### DIFFUSION TENSOR IMAGING

Diffusion tensor imaging (DTI), a recent advance in MRI methods, is uniquely suited to the study of subtle white matter abnormalities that are not detected by traditional MRI. DTI can be used to quantify the magnitude and directionality of tissue water mobility (i.e. self-diffusion). Barriers such as myelin sheaths, membranes, or white matter tracts result in greater self-diffusion along the axis of the barrier and reduced diffusion out of the tract. This type of restricted self-diffusion is termed 'anisotropic'. Fractional anisotropy (FA) is a measure derived from the diffusion tensor imaging that assesses the degree of anisotropic self-diffusion, i.e. the integrity of the white matter tract.<sup>14</sup> The higher the FA the healthier the tract; lower FA indicates damage to its integrity. DTI provides us with information about the large-scale networks that are made up of long tracts connecting distant relay stations in the brain (Fig. 1).<sup>15</sup> These networks are important for the development of higher brain functions such as language, praxis, social behaviour and emotion. Lesions affecting white matter connections lead to dysfunction, and cognitive disorders are sometimes better explained by a disconnection mechanism between distant cerebral regions than by primary damage of those regions themselves.<sup>16</sup>

### DTI IN HIV

DTI studies have revealed central nervous system abnormalities in asymptomatic HIV-positive patients with no cognitive impairment and normal structural



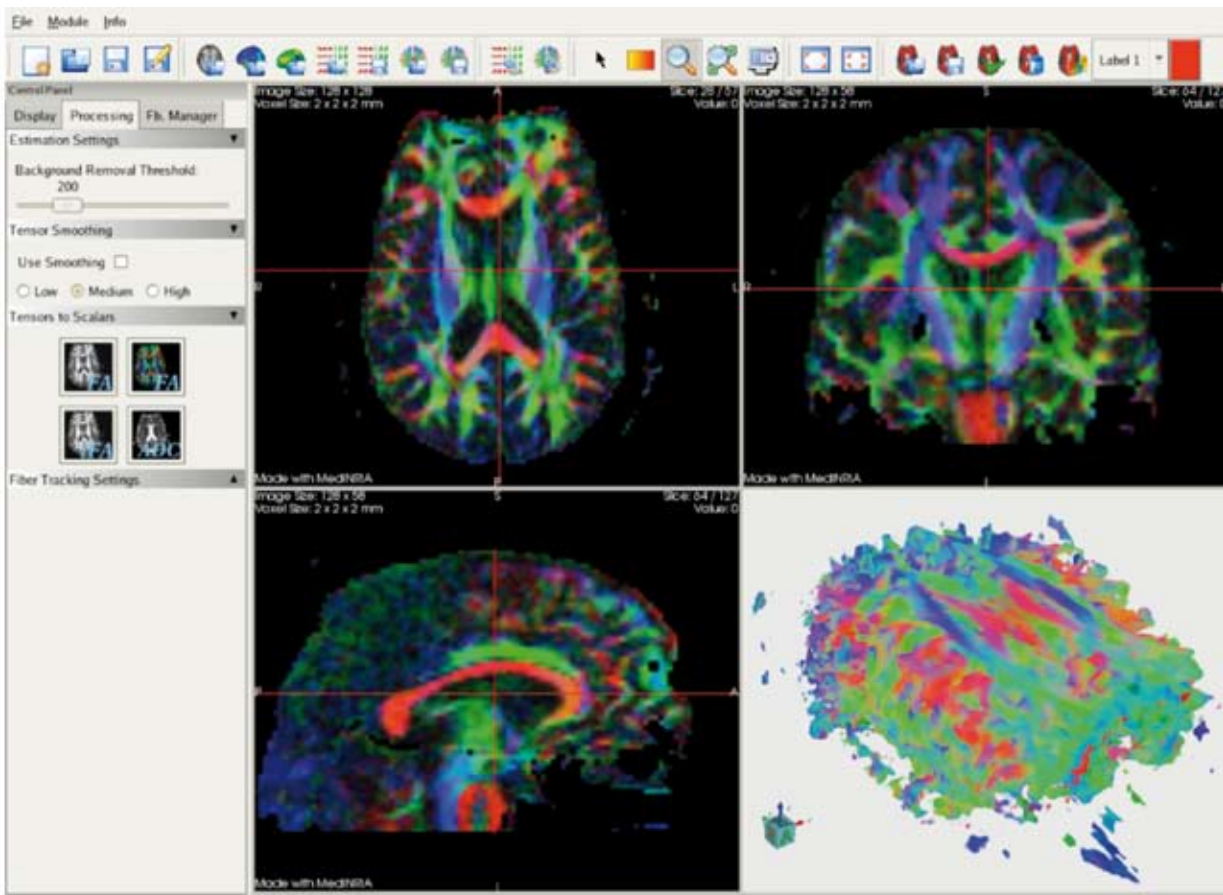

Fig. 1. DTI tractography showing axial, sagittal and coronal views in an individual patient. Areas shaded green represent white matter tracts from anterior to posterior, those in blue inferior to superior, those in red, from left to right. It is possible to isolate regions of interest, or to detect areas where significant abnormalities in integrity of white matter occur.

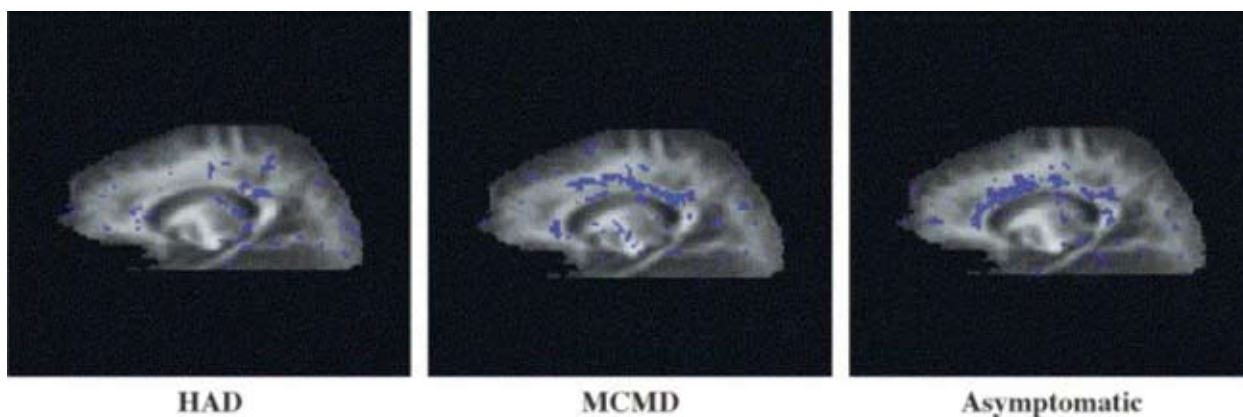


Fig. 2. DTI images showing changes in FA in three groups of patients by clinical severity. These changes reflect significant differences between the groups compared with HIV-negative controls, and indicate (i) that FA is impaired across the spectrum of HIV-associated neurocognitive disorder, including asymptomatic neuropsychological impairment, and (ii) that different regions may be affected across different severities, with some affected areas being responsible for a greater degree of clinical impairment. The amount of FA does not correspond to the location or severity of FA.

MR studies. Diffuse damage to cerebral white matter, as evidenced by pallor on DTI, is one of the most frequent neuropathological features of HIV-1 infection and has been found to be particularly prominent in the advanced stages of the disease.<sup>17</sup> The white matter pallor has been found to be more prevalent and severe in patients with HAD.<sup>17</sup>

DTI abnormalities have been reported in the frontal white matter of cognitively asymptomatic patients infected with HIV,<sup>18</sup> and MR spectroscopy studies indi-

cate that this region may be subject to early injury in patients infected with HIV.<sup>19</sup>

Studies utilising DTI have identified sub-cortical white matter and corpus callosum abnormalities in patients with HIV, despite normal-appearing white matter on MR and non-focal neurological examinations<sup>20</sup> (Fig. 2). Patients with the largest anisotropy decreases had the most advanced HIV disease. Interestingly, patients with the lowest viral loads and normal anisotropy were receiving HAART. This has led some to suggest that DTI

could be used as a potential biomarker of brain injury in patients infected with HIV.<sup>21</sup>

## CONCLUSION

DTI and other emerging neuro-imaging technologies may provide markers for early CNS disease in HIV-positive patients, allowing for the earliest possible detection of cognitive impairment. This in turn may facilitate early preventive antiretroviral treatment to reduce long-term damage. Novel imaging techniques such as DTI applied in individuals with mild forms of neuro-cognitive disorder may be a good place to start. Studies examining response to HAART in patients infected with HIV will be important to determine whether DTI abnormalities reflect reversible or more advanced, irreversible injury. Correlates of white matter damage and neurocognitive decline need to be sought, including whether measures of white matter damage in the central nervous system correlate with viral load, illness duration, age, treatment exposure and treatment adherence. These factors are almost certainly critical in determining the overall impact of HIV on brain function, and in particular on white matter integrity.

## REFERENCES

1. Grant I, Sacktor N, McArthur J. HIV and neurocognitive disorders. In: Gendelman H, Grant I, Everall I, Lipton S, Swindells S, eds. *The Neurology of AIDS*. Oxford: Oxford University Press, 2005.
2. Chang L, Ernst T, Leonido-Yee M, et al. Highly active antiretroviral therapy reverses brain metabolite abnormalities in mild HIV dementia. *Neurology* 1999; 53: 782-789.
3. Ernst T, Chang L, Jovicich J, Ames N, Arnold S. Abnormal brain activation on functional MRI in cognitively asymptomatic HIV patients. *Neurology* 2002; 59: 1343-1349.
4. Tozzi V, Balestra P, Galgani S, et al. Positive and sustained effects of highly active antiretroviral therapy on HIV-1-associated neurocognitive impairment. *AIDS* 1999; 13(14): 1889-1897.
5. Ferrando S, van GW, McElhiney M, Goggin K, Sewell M, Rabkin J. Highly active antiretroviral treatment in HIV infection: benefits for neuropsychological function. *AIDS* 1998; 12(8): F65-F70.
6. Langford TD, Letendre SL, Larrea GJ, Masliah E. Changing patterns in the neuropathogenesis of HIV during the HAART era. *Brain Pathol* 2003; 13: 195-210.
7. Nath A, Schiess N, Venkatesan A, Rumbaugh J, Sacktor N, McArthur J. *Evolution of HIV Dementia with HIV Infection*. Baltimore, Md: Department of Neurology, Johns Hopkins University, 2007.
8. Bell JE. An update on the neuropathology of HIV in the HAART era. *Histopathology* 2004; 45: 549-559.
9. Stout JC, Ellis RJ, Jernigan TL, et al. Progressive cerebral volume loss in human immunodeficiency virus infection: a longitudinal volumetric magnetic resonance imaging study. HIV Neurobehavioral Research Center Group. *Arch Neurol* 1998; 55: 161-168.
10. Tucker KA, Robertson KR, Lin W, et al. Neuroimaging in human immunodeficiency virus infection. *J Neuroimmunol* 2004; 157: 153-162.
11. Berger JR, Nath A, Greenberg RN, et al. Cerebrovascular changes in the basal ganglia with HIV dementia. *Neurology* 2000; 54: 921-926.
12. Brew BJ, Rosenblum M, Cronin K, Price RW. AIDS dementia complex and HIV-1 brain infection: clinical-virological correlations. *Ann Neurol* 1995; 38: 563-570.
13. Avison MJ, Nath A, Greene-Avison R, Schmitt FA, Greenberg RN, Berger JR. Neuroimaging correlates of HIV-associated BBB compromise. *J Immunol* 2004; 157: 140-146.
14. Basser PJ. Inferring microstructural features and the physiological state of tissues from diffusion-weighted images. *NMR in Biomedicine* 1995; 8(7/8): 333-344.
15. Musulam M-M. Imaging connectivity in the human cerebral cortex: the next frontier? *Ann Neurol* 2005; 57: 5-8.
16. Catani M. Diffusion tensor magnetic resonance imaging tractography in cognitive disorders. *Curr Opin Neurol* 2006; 9(6): 599-606.
17. Gray F, Scaravilli F, Everall I, et al. Neuropathology of early HIV-1 infection. *Brain Pathol* 1996; 6(1): 1-15.
18. Pomara N, Crandall DT, Choi SJ, Johnson G, Lim KO. White matter abnormalities in HIV-1 infection: a diffusion tensor imaging study. *Psychiatry Res Neuroimaging* 2001; 106: 15-24.
19. Chang L, Lee PL, Yiannoutsos CT, et al. A multicenter *in vivo* proton-MRS study of HIV-associated dementia and its relationship to age. *Neuroimage* 2004; 23: 1336-1347.
20. Filippi CG, Ulug AM, Ryan E, Ferrando SJ, van Gorp W. Diffusion tensor imaging of patients with HIV and normal-appearing white matter on MR images of the brain. *AJNR Am J Neuroradiol* 2001; 22: 277-283.
21. Wu Y, Storey P, Cohen BA, Epstein LG, Edelman RR, Ragin AB. Diffusion alterations in corpus callosum of patients with HIV. *Am J Neuroradiol* 2006; 27: 656-660.

