

Haemorrhage in intracranial tuberculosis

M Modi

FCRad (SA), MMed

*Department of Radiation Sciences
University of the Witwatersrand
Johannesburg*

A Mochan

FCP (SA)

G Modi

PhD (Lond), FCP (SA), FRCP (Lond)

*Department of Neurosciences
University of the Witwatersrand
Johannesburg*

M J Hale

FCPath (SA)

*Department of Anatomical Pathology
University of the Witwatersrand
Johannesburg*

Introduction

Intracranial tuberculosis is an important cause of morbidity and mortality in developing countries where tuberculosis is endemic.¹ In the central nervous system tuberculosis manifests as cerebritis, cerebral abscess, tuberculoma, and tuberculous meningitis (TBM).¹⁻⁵ TBM is thought to arise from cerebrospinal fluid (CSF) seeding of a ruptured pial or subependymal granuloma.²⁻⁵ Tuberculomata result from haematogenous dissemination and histologically are granulomas with central areas of caseous necrosis.²⁻⁵ Tuberculomata may develop whilst patients are on treatment for TB.⁶

The co-occurrence of intracranial tuberculoma and TBM is well recognized.²⁻⁵ Medical therapy is effective for both forms, with a high cure rate in TBM, and a regression in size of the lesion with improvement of neurological deficit in tuberculoma.¹⁻⁶

Deterioration in patients with TBM is caused by the development of obstructive hydrocephalus or cerebral infarction on the basis of endarteritis.¹⁻⁷ Deterioration in patients with tuberculoma may result from paradoxical expansion of the lesion, poor treatment compliance, and postulated haemorrhage into the tuberculoma.^{5,6} Intracranial haemorrhage as a complication of TBM has been described, albeit rarely.⁸⁻¹⁶ There are a few case reports of patients with TBM complicated by intraventricular, intracerebral and subarachnoid haemorrhage on an aneurysmal or non-aneurysmal basis.⁸⁻¹⁶

We describe here a patient with TBM and an associated left cerebellar tuberculoma who suddenly deteriorated and died on treatment. A large haemorrhage involving the right cerebellum, with subarachnoid extension was demonstrated on computed tomography (CT) scan of the brain and at postmortem. These findings are discussed with respect to the possible mechanism/s of haemorrhage in intracranial tuberculosis.

Case report

A 22-year-old black female patient presented with headache, drowsiness and disorientation. Clinically she had marked neck stiffness, multiple cranial nerve palsies (right third and seventh, bilateral sixth), and bilateral pyramidal tract signs. Fundoscopy was normal. The patient was HIV-negative. CSF analysis revealed a protein of 5 g/100 ml, 81 lymphocytes per ml, 3 neutrophils per ml, glucose of 1.9 mmol/l and a positive TB enzyme-linked immunosorbent assay (ELISA). CT scan of the brain showed a left cerebellar ring-enhancing mass lesion abutting the adjacent brainstem, hydrocephalus with obstruction at the fourth ventricle, and increased basal meningeal enhancement (Fig. 1a). A diagnosis of TBM with left cerebellar tuberculoma and obstructive hydrocephalus was made. Oral anti-tuberculous therapy (4-drug regimen) was commenced. Gradual clinical improvement was noted with complete resolution of the sixth nerve palsies and partial resolution of the right third and seventh nerve palsies. Serial fortnightly CT scans revealed diminishing diameter of the tuberculoma, and resolution of the hydrocephalus.

Approximately 9 weeks after commencing anti-tuberculous therapy, the patient developed a sudden severe generalised headache and became comatose. A CT scan of the brain revealed a large haemorrhage in the right cerebellar hemisphere with extension into the brainstem and the subarachnoid space (Fig. 1b). The patient died shortly thereafter.

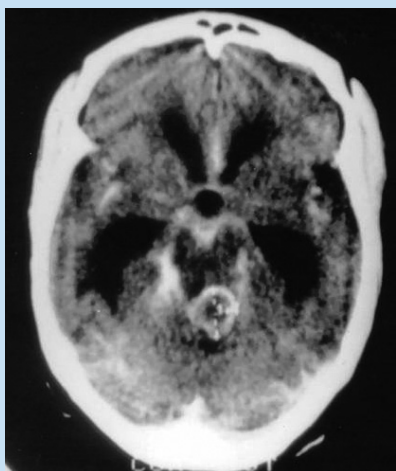


Fig. 1a. CT scan of the brain (post intravenous contrast) in a patient with tuberculous meningitis demonstrating a left cerebellar enhancing lesion abutting the adjacent brainstem (tuberculoma); increased basal meningeal enhancement and obstructive hydrocephalus with associated subependymal oedema.

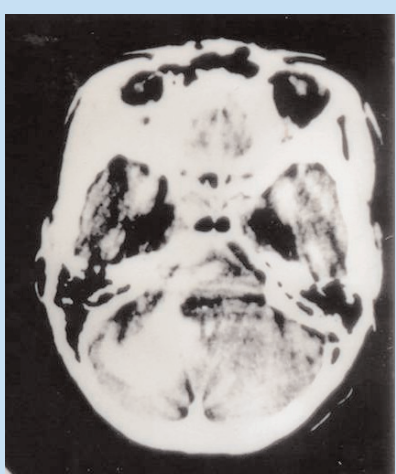


Fig. 1b. CT scan of the brain (non-contrast) demonstrating a large right-sided cerebellar haemorrhage with extension into the adjacent brainstem and subarachnoid space.

Autopsy findings

Examination of the cranial contents revealed extensive subarachnoid haemorrhage overlying the brainstem on the right extending caudally to involve the right cerebellum and obscuring the Circle of Willis. A leptomeningitis was present. A 10 mm tuberculoma was found in the left cerebellar hemisphere. Examination of the left vertebral artery showed sev-

eral small white nodules (granulomas) on the adventitia running along its length.

Microscopically, the meninges showed a florid granulomatous inflammatory reaction with caseous necrosis, epithelioid histiocytes, and cuffing by lymphocytes and plasma cells. The left vertebral artery and many of the meningeal arteries and arterioles showed pronounced intimal proliferation and endarteritis obliterans associated with fibrin platelet thrombus and total vascular occlusion.

A striking feature seen in some vessels was fragmentation and loss of the internal elastic lamina (Fig. 2). This occurred in areas of the vessel wall where granulomatous inflammation (Fig. 2, arrow) was present in the adventitia. A specific site of origin for the subarachnoid haemorrhage was not identified. The lesion in the left cerebellar hemisphere showed histopathological features of a tuberculoma and was surrounded by a moderate degree of perilesional oedema.

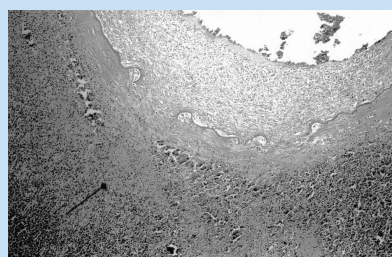


Fig. 2. Photomicrograph showing a medium-sized artery exhibiting fragmentation and loss of the internal elastic lamina accompanied by granulomatous inflammation in the adventitial tissue (arrow). (H&E - original magnification x 100).

Discussion

Intracranial haemorrhages secondary to or in association with TBM have been ascribed to aneurysmal

rupture following the formation of mycotic aneurysms, or to non-aneurysmal rupture as a consequence of weakening of the vessel wall by the granulomatous inflammation.⁸⁻¹⁶ In terms of the latter it has been proposed (but to date not pathologically proven as far as we are aware) that the granuloma produces disintegration of a vessel wall with resultant haemorrhage.¹³ Tuberculoma in association with an A-V fistula causing haemorrhage has also been described.¹⁷

In our patient at autopsy we found numerous deficiencies in the internal elastic lamina of the meningeal blood vessels in addition to the expected intimal proliferation and endarteritis obliterans with fibrin platelet thrombus and vascular occlusion. The deficiencies or fragmentations of the internal elastic lamina were found in areas of the vessel wall where granulomatous inflammation was present, providing the pathological evidence for the proposed mechanism of non-aneurysmal haemorrhage in patients with TBM. The granuloma in the adventitia invades and gradually weakens the vessel wall leading to disintegration as represented by the fragmentation of the internal elastic lamina seen in our case, with or without mycotic aneurysm formation and consequent rupture.

The pathological process described in the meningeal vessels is akin to that which occurs in the pulmonary circulation with pulmonary tuberculosis except that in the pulmonary vessels the chronic granulomatous infiltrate not only causes inflammatory disintegration of the wall but leads to aneurysm formation as described by Rasmussen.¹⁸ Rupture of the aneurysm results in pulmonary haemorrhage and haemoptysis. In the

brain we propose that this process results in haemorrhage in the intracerebral, intraventricular, and subarachnoid spaces.

Our case highlights intracranial haemorrhage as a potential additional cause of death in TBM. Treatment would require search for an aneurysm if patients survive. This has been reported previously.¹⁵ The use of steroids in our patient to prevent or reduce the inflammatory response and the accompanying vasculitis is contentious. Had the patient been treated with steroids from the outset, is it possible that the disintegration of the internal elastic lamina by the inflammatory process would not have occurred and the consequent rupture with haemorrhage could have been prevented. A Cochrane database review concluded that adjunctive steroids might be of benefit in patients with TBM, but the evidence is inconclusive.¹⁹

References

1. Karstaedt AS, Valtchanova S, Barriere R, Crewe-Brown HH. Tuberculous meningitis in South African urban adults. *QJM* 1998; **91**: 743-747.
2. Gray F, Nordmann P. Bacterial infections. In: Graham DI, Lantos PL, eds. *Greenfield's Neuropathology*. 6th ed. Vol 2. London: Arnold, 1997: 130-132.
3. Esiri MM, Oppenheimer DR. *Diagnostic Neuropathology*. Oxford: Blackwell, 1989: 131-133.
4. Berger JR. Tuberculous meningitis. *Curr Opin Neurol* 1994; **7**: 191-200.
5. Campi de Castro C, Garcia de Barros N, de Sousa Campos ZM, Cerri GG. CT scans of cranial tuberculosis. *Radiol Clin North Am* 1995; **33**: 753-769.
6. Awada A, Daif AK, Pirani M, Khan MY, Memish Z, Al Rajeh S. Evolution of brain tuberculomas under standard antituberculous treatment. *J Neurol Sci* 1998; **156**: 47-52.
7. Leiguarda R, Berthier M, Starkstein S, Noguez M, Lylyk P. Ischaemic infarction in 25 children with tuberculous meningitis. *Stroke* 1988; **19**: 200-204.
8. Shuangshoti S, Phisitbutr M. Fatal haemorrhage in tuberculosis of the brain. *J Med Assoc Thai* 1979; **62**: 639-645.
9. Modilevsky T, Arlazoroff A, Goldenberg E, Marmor A. Spontaneous subarachnoid bleeding and stroke syndrome in tuberculous meningoencephalitis. *Harefuah* 1979; **97**: 68-70.
10. Xiao ZX. Haemorrhagic tuberculous meningitis: a report of 10 cases (authors translation). *Zhonghua Jie He He Hu Xi Xi Ji Bing Za Zhi* 1981; **4**: 172-173.
11. Hu CH. Tuberculous meningitis complicated by massive intracerebral haemorrhage. Report of two cases. *Chug-Hua Shen Ching Ching Shen ko Tsa Chih (Chinese Journal of Neurology and Psychiatry)* 1986; **19**: 119-121.
12. Mohapatra AK, Sharma SN, Sethi PK, Ahuja IM. Subarachnoid haemorrhage in tubercular meningitis. *J Assoc Physicians India* 1988; **36**: 237.
13. Roh J, Kang D. A case of tuberculous meningitis complicated by intracerebral haemorrhage. *Eur Neurol* 1998; **40**: 50-52.
14. Nakayama Y, Tanaka A, Nagasaka S, Ikui H. Intracerebral haemorrhage in a patient with moyamoya phenomenon caused by tuberculous arteritis: a case report. *No Shinkei Geka* 1999; **27**: 751-755.
15. Griffiths SJ, Sgouros S, James G, John P. Intraventricular haemorrhage due to ruptured posterior inferior cerebellar artery aneurysm in tuberculous meningitis. *Childs Nerv Syst* 2000; **16**: 872-874.
16. Yeh, ST, Lee W, Lin H, Chen C, Te AL, Lin H. Nonaneurysmal subarachnoid haemorrhage secondary to tuberculous meningitis: report of two cases. *J Emerg Med* 2003; **25**: 265-270.
17. Pathare AV, Patil RR, Chikhalikar AA, Dalvi SG. Association of tuberculoma with arteriovenous malformation (a case report). *J Postgrad Med* 1988; **34**: 190-192.
18. Corrin B. *Pathology of the Lungs*. Edinburgh: Churchill Livingstone, 2001: 391.
19. Prasad K, Volmink J, Menon GR. Steroids for treating tuberculous meningitis. *Cochrane Database Syst Rev* 2000; **3**: CD002244.