

Breast hamartoma: Is this an uncommon or an under-recognised lesion?

Author:Sharon Miller¹**Affiliation:**¹Department of Radiology, University of Pretoria, South Africa**Correspondence to:**

Sharon Miller

Email:

sharonmiller4@gmail.com

Postal address:

1501/92-100 Quay Street, Brisbane City 4000 QLD, Australia

Dates:

Received: 23 June 2014

Accepted: 28 Aug. 2014

Published: 26 Mar. 2015

How to cite this article:Miller, S. Breast hamartoma: Is this an uncommon or an under-recognised lesion?. *S Afr J Rad.* 2015;19(1); Art. #675, 2 pages. <http://dx.doi.org/10.4102/sajr.v19i1.675>**Copyright:**

© 2015. The Authors.

Licensee: AOSIS

OpenJournals. This work is licensed under the Creative Commons Attribution License.

A hamartoma is a disorganised focus of a mature overgrowth of cells composed of tissue elements of the organ in which it is found, and it can occur anywhere in the body. A breast hamartoma is a rare, benign tumour consisting of fat, glandular and fibrous tissue, and is known by various names such as lipofibroadenoma or fibroadenolipoma, depending on the dominant tissue found within the lesion. The reported incidence is low (0.1% – 0.7%), but is increasingly thought to be because of under-diagnosis of the condition.

Introduction

Breast hamartomas are uncommon lesions with a low incidence, according to the literature, but this may also be the result of under-diagnosis. The reported incidence in the literature is between 0.1% and 0.7%, as described by Arrigoni et al. in 1971.¹ The lesion is known by several names: fibroadenolipoma, lipofibroadenoma or adenolipoma.² Clinically, it is a painless, smooth, mobile breast lump that may or may not be palpable and can slowly enlarge in size.³ Radiologically, small lesions may appear as normal breast tissue but larger lesions tend to develop a characteristic appearance. We describe a case of hamartoma of the breast with typical radiological features that allow a diagnosis to be made without biopsy.

Case report

A 38-year-old woman presented with a palpable, soft, mobile, non-tender breast lump in the supra-areola region of the right breast. On enquiry, she revealed that it had been present at her previous ultrasound performed at another practice and had not changed in size or consistency in the last 12 months. The patient had been informed by the radiologist at the time that it was a rare type of benign fatty tumour that should not cause any concern.

The mammogram demonstrated a well-circumscribed lesion in the right breast supra-areolar region, with a heterogeneous density and a thin uniform radiodense pseudocapsule (Figure 1).

On ultrasound, a well-circumscribed breast lesion was noted in the 12 o'clock position that demonstrated a mixed echogenic pattern with a predominant echogenic pattern consistent with fat (Figure 2). In comparison with the previous ultrasound study, as indicated on the report, the lesion had not changed in size or character significantly.

After consultation and discussion with the patient, no further management other than regular self-examinations and follow-up breast screening was recommended. The patient was advised to seek immediate attention, however, if any change in the size or nature of the lesion was detected.

Discussion

Breast hamartomas are benign breast tumours described as resembling a 'breast within a breast' on mammography.⁴ They have a heterogeneous density with a mottled centre and are usually round or ovoid, with a well-circumscribed pseudo-capsule that results from the displacement and compression of surrounding breast tissue.³ Coarse or punctate calcifications are rarely seen within the lesion.²

On ultrasound, the features may appear as normal breast tissue or a well-circumscribed oval, solid mass that is predominantly hypoechoic but may present with a mixed echogenicity owing to the presence of adipose and fibroglandular tissue. The tumour is easily compressible when pressure is applied with a transducer.⁵

Some articles in the literature^{3,4} describe the presence of coexistent malignancy in a small percentage of hamartomas whilst others indicate that there may be a low risk of malignant transformation. Patient education regarding the importance of self-examination and compliance with follow-up

Read online:

Scan this QR code with your smart phone or mobile device to read online.

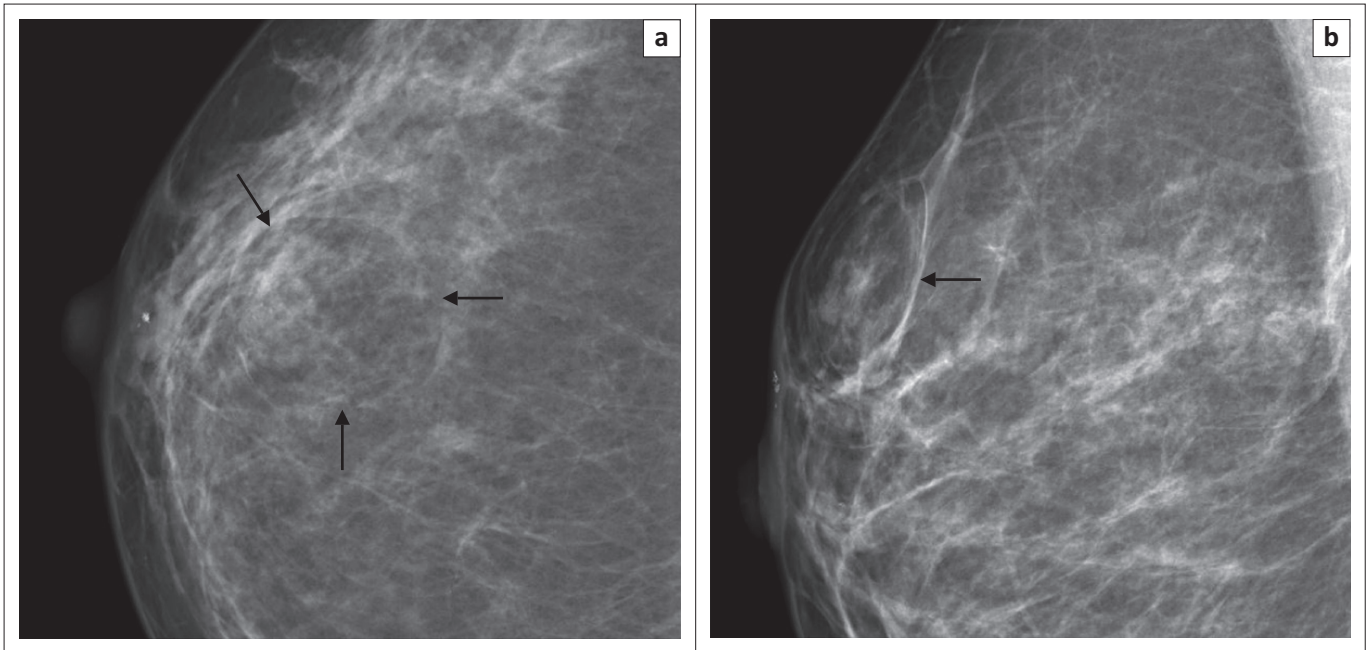


FIGURE 1: Craniocaudal (a) and mediolateral oblique (b) mammogram views of the right breast, demonstrating a well-circumscribed heterogeneous mass in the supra-areolar region of the right breast (arrows). Note the radiodense pseudocapsule.

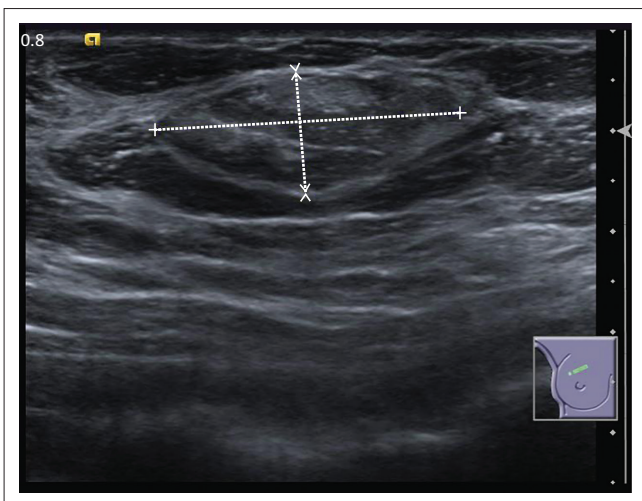


FIGURE 2: Ultrasound image at the 12 o'clock position of the right breast demonstrates a well-defined oval lesion with a mixed echogenic pattern.

must therefore be emphasised, and the radiologist should always be vigilant about any small change within the tumour.

Regarding definitive diagnosis of a breast hamartoma, views differ. Most advocate that fine-needle aspiration (FNA) or core biopsy has a limited role, and recommend full excision biopsy for a better diagnosis. If a biopsy is not done, then regular clinical and radiological follow-up is recommended.

Conclusion

Breast hamartomas are rare benign breast tumours that, whilst having characteristic radiological findings, do not

possess definitive histological features and can often be reported as normal breast tissue. It is therefore important to have good clinical, radiological and histological correlation to avoid under-diagnosing such lesions.⁶ If a biopsy is going to be performed, excision biopsy is recommended rather than FNA or core biopsy.

With the increasing practice of mammographic breast screening, it is important for the radiologist to be aware of this tumour and to pay attention to the clinical information and good radiological correlation.

Acknowledgements

Competing interests

The author declares that she has no financial or personal relationship(s) that may have inappropriately influenced her in writing this article.

References

1. Arrighoni MG, Dockerty MB, Judd ES. The identification and treatment of mammary hamartoma. *Surg Gynecol Obstet.* 1971;133:577–582.
2. Feder JM, de Paredes ES, Hogge JP, Wilken JJ. Unusual breast lesions: Radiologic-pathologic correlation. *Radiographics.* 1999;19:11–26. http://dx.doi.org/10.1148/radiographics.19.suppl_1.g99oc07s11
3. Wei-Feng L, Shyr-Ming S, Shun-Yu C, Hsuan-Ying H, Sheung-Fat K. Hamartoma of the breast: An underrecognised disease? *Tumori.* 2008;94:114–115.
4. Sonmez FC, Gucin Z, Yildiz P, Tosuner Z. Hamartoma of the breast in two patients: A case report. *Oncol Lett.* 2013;6:442–444.
5. Rohini A, Prachi K, Vidyabargavi. Multimodality imaging of giant breast hamartoma with pathological correlation. *International J of Basic and Appl. Med. Sci.* 2014;4:278–281.
6. Tse GMK, Law BKB, Ma TKF, et al. Hamartoma of the breast: A clinicopathological correlation. *J Clin Pathol.* 2002;55:951–954. <http://dx.doi.org/10.1136/jcp.55.12.951>