

# Persistent hyperplastic primary vitreous – The martini glass sign

## Author:

A. Fourie Bezuidenhout<sup>1</sup>

## Affiliation:

<sup>1</sup>Department of Radiodiagnosis, Stellenbosch University, South Africa

## Correspondence to:

Fourie Bezuidenhout

## Email:

fouriebez@yahoo.com

## Postal address:

PO Box 19179, Tygerberg 7505, South Africa

## Dates:

Received: 07 Jan. 2014

Accepted: 16 Feb. 2014

Published: 20 June 2014

## How to cite this article:

Bezuidenhout AF. Persistent hyperplastic primary vitreous – The martini glass sign. *S Afr J Rad.* 2014;18(1); Art. #597, 1 page. <http://dx.doi.org/10.4102/sajr.v18i1.597>

## Copyright:

© 2014. The Authors. Licensee: AOSIS OpenJournals. This work is licensed under the Creative Commons Attribution License.

## Read online:



Scan this QR code with your smart phone or mobile device to read online.

Persistent hyperplastic primary vitreous (PHPV) is a congenital lesion due to incomplete regression of the embryonic ocular blood supply (hyaloid vasculature).<sup>1</sup> It represents 28% of childhood presentations of leukocoria and is almost always accompanied by poor vision, microphthalmia and often retinal detachment.<sup>1,2,3</sup> The absence of ocular calcifications helps distinguish PHPV from the more common retinoblastoma.<sup>4</sup> The appearance of PHPV has been likened to that of a martini glass. The martini glass is represented by triangular retroretinal fibrovascular tissue and a central tissue stalk of hyaloid remnant extending to the optic disc in Cloquet's canal (see Figure 1a).<sup>5</sup> The retroretinal fibrovascular tissue and stalk-like hyaloid remnant are hypointense to isointense on T1- and T2-weighted images and show enhancement post contrast administration. The globe may be hyperintense on T1-weighted images; this may represent either subhyaloid or subretinal fluid with blood degradation products (methaemoglobin) or high protein content (see Figure 1b).<sup>1</sup>

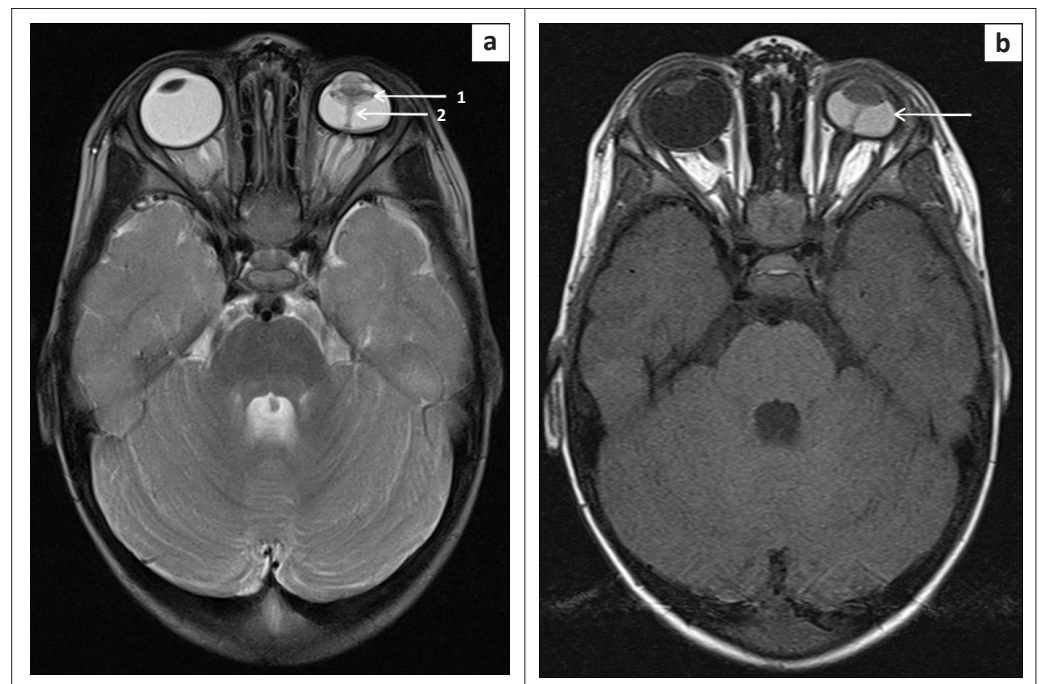
## Acknowledgements

### Competing interests

The author declares that he has no financial or personal relationship(s) that may have inappropriately influenced him in writing this article.

## References

- Smirniotopoulos JG, Bargallo N, Mafee MF. Differential diagnosis of leukocoria: Radiologic-pathologic correlation. *Radiographics.* 1994;14(5):1059–1079. PMID: 7991814. <http://dx.doi.org/10.1148/radiographics.14.5.7991814>
- Küker W, Ramaekers V. Persistent hyperplastic primary vitreous: MRI. *Neuroradiology.* 1999;41(7):520–522. PMID: 10450848. <http://dx.doi.org/10.1007/s002340050796>
- Sun MH, Kao LY, Kuo YH. Persistent hyperplastic primary vitreous: Magnetic resonance imaging and clinical findings. *Chang Gung Med J.* 2003 Apr;26(4):269–276. PMID: 12846526.
- Edward DP, Mafee MF, Garcia-Valenzuela E, Weiss RA. Coats' disease and persistent hyperplastic primary vitreous. Role of MR imaging and CT. *Radiol Clin North Am.* 1998;36(6):1119–1131, x. PMID: 9884692.
- Kaste SC, Jenkins JJ, Meyer D, Fontanesi J, Pratt CB. Persistent hyperplastic primary vitreous of the eye: Imaging findings with pathologic correlation. *Am J Roentgenol.* 1994;162(2):437–440. PMID: 8310942. <http://dx.doi.org/10.2214/ajr.162.2.8310942>



**FIGURE 1:** Axial T2-weighted (a) and axial T1-weighted (b) images show the triangular retroretinal fibrovascular tissue (arrow 1) and a central tissue stalk of hyaloid remnant in Cloquet's canal (arrow 2) representing the 'martini glass' sign; (b) Microphthalmia and hyperintense vitreous (arrow) on T1-weighted image due to accumulation of blood degradation products or high protein content compared to normal right globe.