

## Tattooing gone wrong

Endoscopic tattooing of colonic lesions has become common practice. The dyes selected for tattooing differ depending on what the purpose of the tattoo is. Large polyps for which endoscopic mucosal resection (EMR) is planned are tattooed with diluted methylene blue. This temporarily stains the muscularis propria of the bowel wall and helps safeguard against full thickness resection. The tattoo disappears within a few hours.

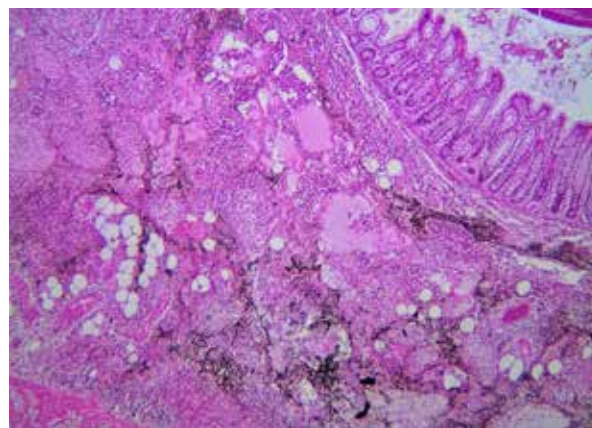
Permanent colonic tattoos are used for where a suspicious polyp has been endoscopically resected and the possibility of malignancy within it is strongly considered, or where a clinically obvious malignant colonic lesion has been identified. This allows accurate surgical planning should histological assessment show cancer within the polyp, and detection of polyp recurrence at the site of the resection on future colonoscopies, if it does not.

Tactile sensation is greatly reduced in minimally invasive surgery and tumour localization based on colonoscopy is notoriously inaccurate.<sup>1</sup> Where colonic lesions are not easily visualized on laparoscopy, a circumferential full-thickness wall tattoo at the site of the lesion assists the surgeon to identify the segment of colon that should be resected, avoid conversion to open surgery and resection of the incorrect segment of bowel.<sup>2</sup>

India ink, in which the black pigment is carbon soot, is the standard dye in all products that can be used to make permanent colon tattoos. Carbon can be obtained from various sources including oil-lamp soot (lamp black), bone, wood and vine char, which is then combined with water. Some products contain colloids, such as shellacs or gelatins, to keep the soot in suspension. These are not present in products that are registered for medical use.

Although there are commercial medical tattooing dyes available (for example SPOT®), they are relatively expensive and the use of non-medical India ink preparations to tattoo lesions in the colon has become commonplace. The safety of this practice has been reported.<sup>3</sup>

We present one case of intramural abscess formation in the sigmoid colon at the site of a permanent tattoo made with non-medical India ink. The standard technique<sup>3</sup> of raising a sub-mucosal bleb with saline prior to tattooing had been used and the patient underwent a laparoscopic sigmoid colectomy the day after the tattoo was placed. There was no macroscopic evidence of the abscess at the time of surgery. However, histological assessment of the bowel showed a well-developed submucosal abscess, containing tattoo pigment, with the suppurative inflammation focally extending into the superficial muscularis propria.



*Abscess with admixed tattoo pigment expanding the submucosa (H&E, 4x magnification)*

This response to tattooing has not been seen by our pathology service before and we are uncertain of its significance. There is usually a time delay of at least 7 days between tattooing and resection in our unit that was not the situation in this case. Whether this response represents what is normal in the evolution of inflammation in the bowel wall against the tattoo, or whether this is a legitimate pathological entity that posed a risk to this patient is uncertain.

We have now abandoned the practice of tattooing colonic lesions with products that are not registered for medical use on the basis of this case and are exclusively using an approved medical dye for our permanent colonic tattoos.

**M I Hampton,<sup>1,2,3</sup> C Warden,<sup>2,3</sup> F Botha<sup>3,4</sup>**

<sup>1</sup>Department of Surgery, Victoria Hospital Wynberg

<sup>2</sup>Department of General Surgery, Groote Schuur Hospital, Colorectal Surgery Unit

<sup>3</sup>University of Cape Town

<sup>4</sup>Division of Anatomical Pathology, Groote Schuur Hospital, National Health Laboratory Service

### REFERENCES

1. Piscatelli N, Hyman N, Osler T. Localizing colorectal cancer by colonoscopy. *Arch Surg.* Oct 2005;140(10):932-5.
2. Conaghan PJ, Maxwell-Armstrong CA, Garrioch MV, Hong L, Acheson AG. Leaving the mark: the frequency and accuracy of tattooing prior to laparoscopic colorectal surgery. *Colo Dis.* Oct 2011;13(10):1184-7.
3. Yeung JMC, Maxwell-Armstrong CA, Acheson AG. Colonic tattooing in laparoscopic surgery – making the mark? *Colo Dis.* Jun 2009;11(5):527-30.