

## AIR RIFLE INJURIES IN CHILDREN\*

L. SPITZ, M.B., CH.B., *Surgical Registrar, Transvaal Memorial Hospital for Children, and University of the Witwatersrand, Johannesburg*

Although the air rifle has long been regarded as a potentially dangerous weapon, no analyses of large series of injuries caused by these weapons have appeared in the medical literature to date. Had Oliver Cromwell been assassinated by the air gun, so hopefully bought for that purpose, or had the American Continent Army adopted the air gun, as was presumably proposed at the time and as Austria did later, and had Napoleon not taken such violent exception to the use of the air gun during his Tyrolean campaign, the subject would not have been so obscure,<sup>1</sup> and legislation regarding the possession of such instruments would no doubt have been introduced.<sup>2</sup>

### LEGISLATION AND BALLISTICS

In South Africa, only air rifles of 0.22-inch and larger calibres, which are capable of being used for propelling any substances or articles, require the possession of a permit under the Arms and Ammunition Act of 1937 as amended on 30 September 1960.

Similar legislation exists in the United Kingdom. In New Zealand legislation requires that persons under the age of 21 years, but above 16 years, must obtain a police permit (with parental consent) before the purchase of an air rifle in the 0.177-inch calibre range. Persons under the age of 16 years are not entitled to use an air rifle without parental supervision.

The average velocity at a range of 6 ft of the pellet produced by spring air rifles in the 0.177-inch calibre range varies from 400 ft/sec. in the junior type air rifle to 600 ft/sec. in the most powerful air rifle. The penetration power, as assessed by the number of strawboards,  $\frac{3}{4}$  inch thick, placed  $\frac{1}{2}$  inch apart, penetrated at 20 ft, varies from 12 to 16. Comparative figures for the 0.22-inch calibre air rifle are a velocity of 540 ft/sec. and a penetration power of 18 strawboards.<sup>3</sup>

Human tissues offer no barrier to the penetration of a pellet, and injuries of a serious nature occurred in 30% of the cases analysed in this series. The calibre of the stan-

dard pellet in South Africa is 0.177 inch (4.5 mm.) and all cases included in this series concern injuries caused by the pellet of 0.177-inch calibre.

All cases with air rifle injuries severe enough to warrant admission to hospital, since 1959, have been analysed. Radiological confirmation of the presence of a pellet was obtained on admission in all cases.

### ANALYSIS OF CASES

In the 9-year period under review, 85 cases of penetrating pellet injuries were treated by members of the paediatric surgical staff. Fig. 1 shows the annual incidence of the cases.

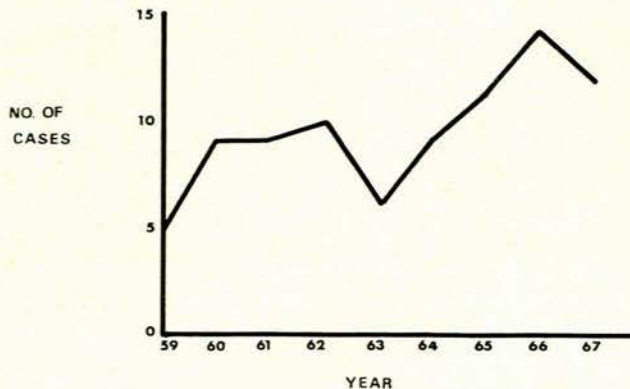


Fig. 1. Annual incidence.

### Race and Sex

All patients were of Caucasian origin (Transvaal Memorial Hospital being an exclusively White hospital), 70 being male and 15 female, resulting in a ratio of 4.7 males to 1 female.

### Age

The age distribution is illustrated in Fig. 2. As expected, the greatest incidence was between the ages of 10 and 14 years. There was little difference in the percentage of males as compared with females in each age-group.

\*Date received: 6 August 1968.

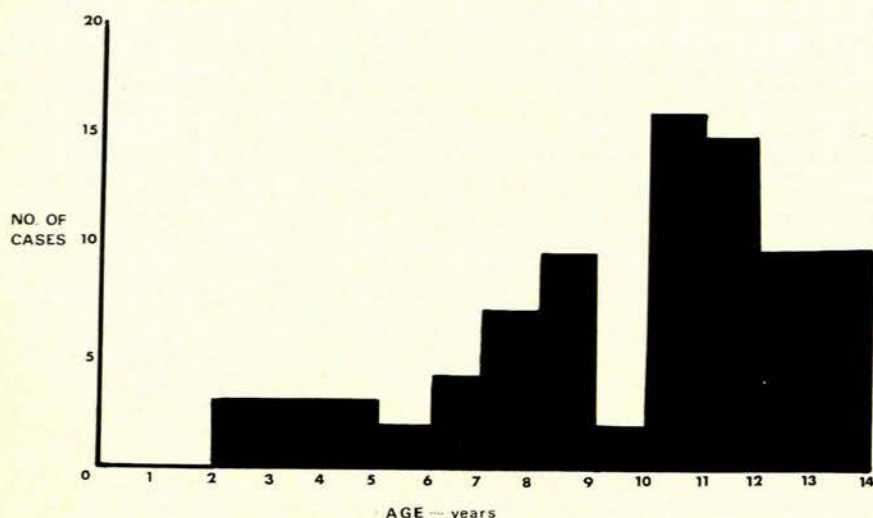


Fig. 2. Distribution according to age.

#### Site of Lesion

The frequency with which various parts of the body were affected is shown in Table I. The lower extremity was most

TABLE I. LOCATION FREQUENCY

Part of body	No. of cases
Head and neck	24
Face	15
Eye	7
Neck	2
Thorax	7
Abdomen	4
Upper extremity	20
Arm	6
Forearm	5
Hand	9
Lower extremity	30
Thigh	15
Calf	8
Foot	7
Total	85

often involved, i.e. 35.3%. It is of interest to note that of 4 cases in which the abdomen was the site of injury, penetration of the peritoneum occurred in 3. In other words, laparotomy was performed in 3 of the 4 patients, while in the fourth the progression of the pellet was halted by the posterior rectus sheath. Five of the 7 cases sustaining eye injuries resulted in blindness, one of which was permanent (see below). Penetration of the chest wall occurred in 3 of the 7 cases in which the thorax was involved.

#### Nature of Trauma

Twenty-five percent of cases were self-inflicted due to careless handling of the rifle. All of these occurred in boys. Most of the remainder resulted while groups of children were at play—lack of supervision being a major contributory factor in this group.

#### Treatment

Generally, 3 forms of therapy were adopted:

- (i) Removal under general anaesthesia.
- (ii) Removal under local anaesthesia.
- (iii) Conservative management (pellet left *in situ*).

The indications for exploration under local or general anaesthesia and/or removal of the pellet were as follows:

- (a) Damage to a vital structure, e.g. eye.
- (b) Penetration of peritoneal cavity.
- (c) Suspected trauma to neighbouring structures, e.g. blood-vessels, nerves, etc.
- (d) Penetration into a joint.
- (e) Associated compound fracture.
- (f) Secondary infection.

Where the pellet had penetrated deeply without producing any of the above effects, or where surgical removal was hazardous in view of the situation of the pellet, conservative management was instituted.

#### Mortality and Morbidity

There were no deaths in the series. Wound sepsis after removal occurred in one case where the pellet had lodged in the thenar eminence of the left hand. Wound haematoma developed in one case, and abscess formation after initial conservative therapy occurred in 4 cases: the pellet embedded deeply in the forehead; the pellet in the inner aspect of the left upper arm; the pellet penetrated deeply into the 4th webspace of the right hand; and the pellet lodged in the posterior aspect of the left knee.

The period of hospitalization is illustrated in Fig. 3.

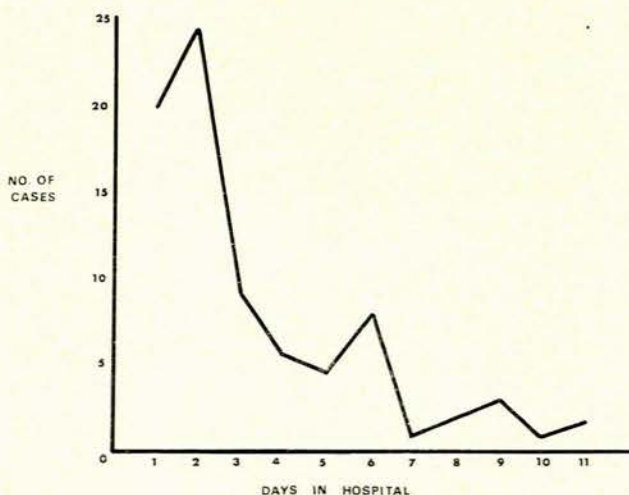


Fig. 3. Duration of hospitalization.

Although most children were discharged from hospital within 3 days, a significant number spent more than a week in hospital. The average duration of stay in hospital was 4.06 days.

## ILLUSTRATIVE CASES

*Case 1*

A boy aged 12 years shot himself accidentally. The pellet penetrated his chest, the entrance wound being situated in the second right intercostal space, 1 inch from the midline. Clinically he was not shocked and examination of the chest was essentially normal. An X-ray showed the pellet to be situated in the anterior mediastinum (Fig. 4). He was treated conservatively and discharged on the 5th day after the accident.

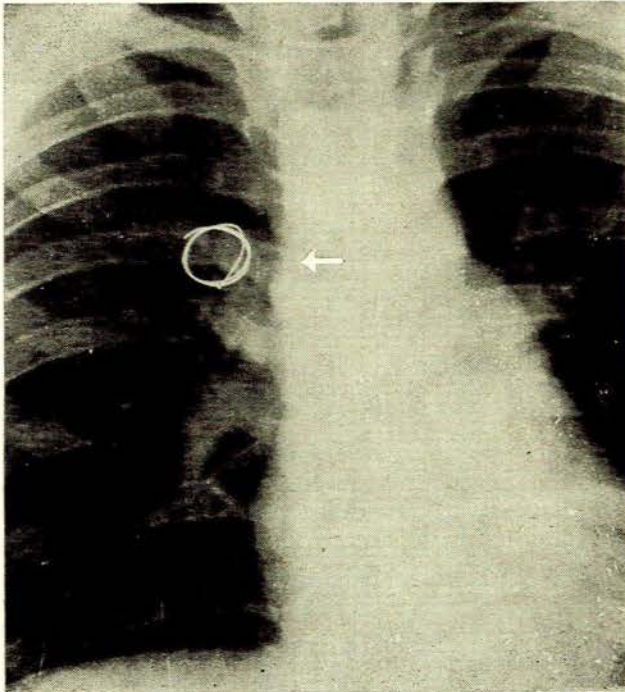


Fig. 4. Chest radiograph showing entrance site and pellet in anterior mediastinum.

*Case 2*

A child aged 2 years was shot accidentally in the right eye. The entrance wound was situated in the inferior corneoscleral junction. The corneal laceration was sutured and wound debridement was carried out under general anaesthesia. A total hyphaema of the right eye developed and total blindness ensued. Due to extensive intra-ocular damage and the danger of sympathetic ophthalmia, the right eye was enucleated 4 weeks after the initial injury and was replaced with an Allen prosthesis. The child spent a total of 25 days in hospital.

*Case 3*

A boy aged 11 years was accidentally shot with an air rifle by his brother. The pellet penetrated his right orbit (Fig. 5), causing severe laceration of the conjunctiva and producing a traumatic retinitis. Debridement and suturing of the conjunctival laceration was performed under general anaesthesia. He spent a total of 8 days in hospital and has permanent impairment of vision.

*Case 4*

A girl aged 9 years was shot in the abdomen with an air rifle. An entrance wound was present 2 inches from the

midline in the left transpyloric plane. At laparotomy, the pellet, which had traversed the left lobe of the liver and was lying free in the gastrohepatic omentum, was removed. She made an uneventful recovery and was discharged on the 8th postoperative day (Fig. 6).

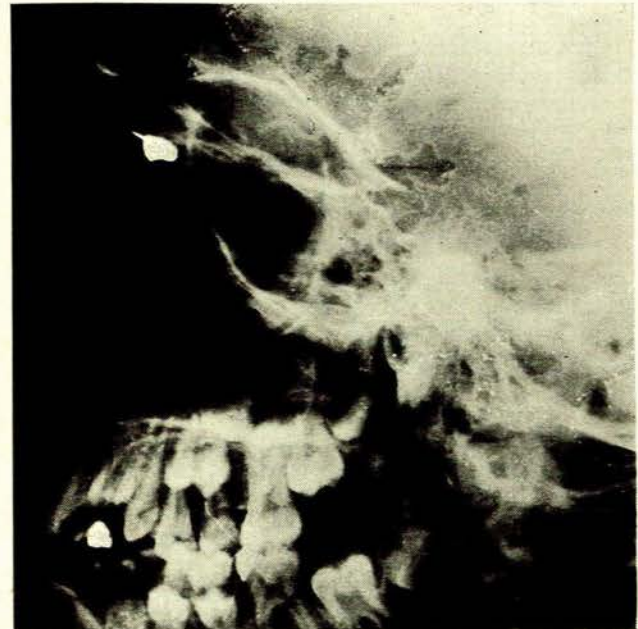

Fig. 5. Lateral facial radiograph showing pellet lying in right orbit.

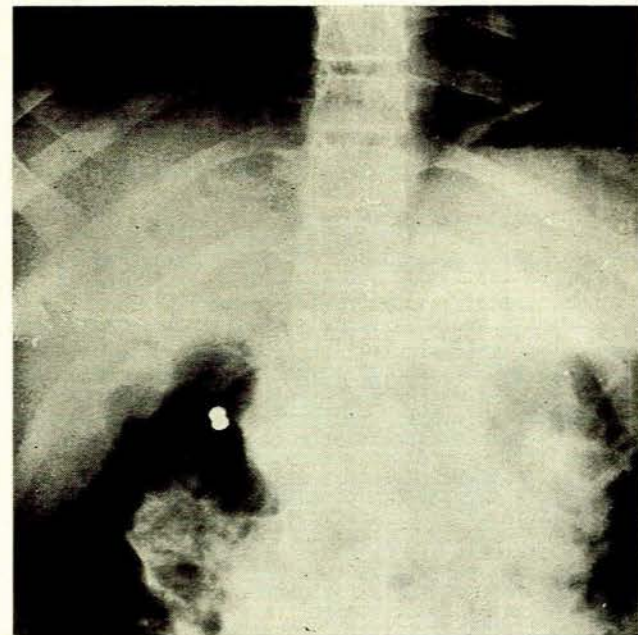


Fig. 6. Erect abdominal radiograph showing pellet to right of midline.

*Case 5*

A girl aged 13 years was shot in the abdomen by an unknown person. On admission she was shocked and pale. An entrance wound was present in the 7th left intercostal space 2 inches from the midline. At laparotomy the pellet

was found to have penetrated the left lobe of the liver and approximately 500 ml. of blood was present in the peritoneal cavity. The pellet was not found. She made an uneventful recovery and was discharged on the 11th postoperative day.

#### Case 6

A boy aged 13 years was shot in the right knee after the air rifle with which he and his brother were playing accidentally discharged. The pellet entered his right knee-joint, causing a large effusion to collect. A medial arthro-tomy was performed under general anaesthesia and the pellet was found in the intercondylar notch. He was discharged well on the 10th postoperative day.

#### DISCUSSION

A total of 302 injuries caused by air guns, air rifles and air pistols were reported to the Department of Justice in Great Britain in the 3-year period ending February 1934. In 63 of the cases the injuries were allegedly of a serious nature.<sup>3</sup>

Menes and Bella<sup>4</sup> reported a case of perforation of 4 abdominal organs by a lead pellet in a child. Penetration of the right ventricle of the heart by a pellet, with embolization into the right brachial artery causing acute ischaemia of the right hand, was recorded by Neerken and Clement.<sup>5</sup>

Seven cases of pellet injuries in New Zealand were analysed by Rawson,<sup>6</sup> of which 2 were of a serious nature; one required laparotomy and repair of a jejunal laceration and in the other the left eye was irreparably damaged. He comments on the unsuitable nature of legislation in that country regarding the possession of such weapons.

The present article has amply illustrated the ability of the pellet in the 0.177-inch calibre range, when used in

the more powerful model air rifles, to penetrate human tissues. The trunk was involved in 11 cases, penetration into the visceral cavity occurring in 54.5% of cases.

It would appear as if the air rifle should fall under the Dangerous Weapons Act No. 54 of 1949 as amended by Section 28 of Act No. 62 of 1955. The Act states that any person who is in possession of a dangerous weapon shall be guilty of an offence unless he is able to prove that such weapon is required by him for a lawful purpose.

It seems incongruous that a weapon with the destructive capacity of the air rifle in the 0.177-inch calibre range does not require a permit. However, an air rifle of 0.22-inch calibre—which, at least in the lower power range, may have a velocity and penetration power lower than the most powerful 0.177-inch calibre air rifle—does require a permit. An amendment to existing legislation to include weapons of 0.177-inch calibre would appear to be warranted.

#### SUMMARY

Eighty-five cases of pellet injuries in children are reported. Injuries of a serious nature occurred in 30% of cases. A plea is made for an amendment to existing legislation to include weapons of 0.177-inch calibre.

I wish to thank Dr H. van Wyk, Medical Superintendent of Johannesburg Hospital, for permission to publish this article, and Mr A. Veenstra for the photographs.

#### REFERENCES

1. Wolff, E. G. (1958): *Air Guns*. Milwaukee, Wis.: North American Press.
2. *Government Gazette*, 30 September 1960, No. 1509.
3. Wesley, L. (1955): *Air Guns and Air Pistols*. London: Cassell.
4. Menes, S. and Bella, R. (1961): *Philipp. J. Surg.*, **16**, 401.
5. Neerken, A. J. and Clement, F. L. (1964): *J. Amer. Med. Assoc.*, **189**, 579.
6. Rawson, H. D. (1965): *N.Z. Med. J.*, **64**, 327.
7. Smith, W. H. B. (1957): *Gas, Air and Spring Guns*. Philadelphia: Military Service Publishing Co.