

CASE REPORT

Fulminant hepatitis B virus (HBV) infection in an infant following mother-to-child transmission of an e-minus HBV mutant: Time to relook at HBV prophylaxis in South African infants

O Babatunde,¹ MBBS, MSCI, FMCPaed; H Smuts,^{2,3} PhD; B Eley,¹ MB ChB, FCP (SA) (Paed), BSc Hons;
S Korsman,^{2,3} MB ChB, FC Path (SA) Viro, MMed; R de Lacy,⁴ MB ChB, FCP (SA) (Paed); D R Hardie,^{2,3} MB ChB, MMed

¹ Paediatric Infectious Diseases Unit, Red Cross War Memorial Children's Hospital, Cape Town, South Africa; and Department of Paediatrics and Child Health, Faculty of Health Sciences, University of Cape Town, South Africa

² National Health Laboratory Service, Groote Schuur Hospital, Cape Town, South Africa

³ Division of Virology, Department of Pathology, Faculty of Health Sciences, University of Cape Town, South Africa

⁴ Gastroenterology Unit, Red Cross War Memorial Children's Hospital, Cape Town, South Africa; and Department of Paediatrics and Child Health, University of Cape Town, South Africa

Corresponding author: D R Hardie (diana.hardie@uct.ac.za)

The prevalence of hepatitis B virus (HBV) infection in pregnant women is high in South Africa (SA), yet prophylaxis to prevent mother-to-child transmission (MTCT) falls short of international recommendations. We describe a 10-week-old infant who developed fulminant hepatic failure following MTCT. The mother was hepatitis e-antibody positive and had a viral load of only 760 IU/mL. Genetic analysis of virus from mother and infant showed that both had the G1896A mutation in the preC/C gene, which truncates hepatitis e antigen (HBeAg) during translation, causing an HBeAg-negative phenotype. HBeAg attenuates antiviral immune responses, and its absence was probably responsible for the infant's fulminant hepatitis, due to an uncontrolled immune attack on infected liver cells. Pregnant women are not tested for HBV infection in SA and MTCT rates are unknown. Addition of a birth dose of vaccine, HBV screening of pregnant women and antiviral prophylaxis to positive mothers should be prioritised.

S Afr Med J 2018;108(5):389-392. DOI:10.7196/SAMJ.2018.v108i5.13017

Sub-Saharan Africa is a region of high hepatitis B virus (HBV) prevalence, where >75% of individuals have evidence of HBV exposure and 10% of people are chronically infected.^[1] HBV is transmitted by parenteral exposure to infected blood or body fluids and from mother to child. Exposure to HBV at an early age increases the chance of persistent infection and is responsible for maintaining the cycle of infection in regions of high endemicity. Prevalence studies conducted in South Africa (SA) before the introduction of infant immunisation suggested that peak acquisition of HBV mainly occurred in children between 1 and 5 years of age and that mother-to-child transmission (MTCT) was uncommon.^[2-4] Accordingly, when the HBV vaccine was added to the infant immunisation schedule in the 1990s, it was given at 6, 10 and 14 weeks of age. Notably, a birth dose of vaccine was omitted for logistical reasons. Since then there has been a dramatic reduction in acute HBV infections and associated disease in children, and carriage rates have also declined.^[5-6] However, HBV infections in children still occur in SA, owing either to gaps in vaccine coverage or MTCT as a result of failed prophylaxis.^[7] The high rate of maternal HIV and HBV co-infection in SA may be another factor increasing transmission risk.^[8-10] Mechanisms of MTCT of HBV are similar to those for HIV and transmission may occur *in utero*, intrapartum or via breast-feeding. Women who are hepatitis e-antigen (HBeAg)-positive with high HBV viral loads (VLs) are more likely to transmit to their infants. Breakthrough infections occur in ~1 - 9% of this group, despite prophylaxis.^[11] Though less common, HBeAg-negative

women can also transmit HBV infection and this can have severe consequences for their infants.^[12]

The current HBV prophylaxis in SA falls woefully short of current international recommendations, namely that all infants should receive a birth dose of HBV vaccine (as recommended by the World Health Organization^[13]), pregnant women should be screened for hepatitis B surface antigen (HBsAg), and HBV VL should be performed on positive patients. Lastly, mothers with HBV VLs >200 000 IU/mL (American Association for the Study of the Liver and European Association for the Study of the Liver) or >6 log IU/mL (Asian Pacific Association for the Study of the Liver) should receive antiviral prophylaxis with lamivudine, telbivudine or tenofovir in the second and third trimesters of pregnancy.^[14]

Case report

A 10-week-old male infant was admitted to Red Cross War Memorial Children's Hospital in Cape Town, SA, on 25 November 2016 with fever and poor feeding of 3 days' duration. He was receiving breast and formula milk feeds. He had received an intramuscular dose of a combination vaccine (HBV, *Haemophilus influenzae* type B, diphtheria, tetanus, acellular pertussis and inactivated polio) 4 days prior to admission. There was no history of diarrhoea, vomiting, cough, seizures, jaundice or recent travel. His mother was from the Democratic Republic of Congo (DRC). She had arrived in Cape Town while pregnant and had a normal vaginal delivery in Cape Town at

39 weeks' gestation. The baby's birth weight was 3 660 g, he had good Apgar scores, birth RPR for syphilis was negative, his immunisation status was up to date, and there was no history of contact with individuals with tuberculosis. He had not received any medication prior to presentation.

At presentation, his temperature was 38.8°C, he was active and not jaundiced, the findings on abdominal examination were normal, and there was no clinically evident focus of infection. Dipstick examination of the urine was negative, cerebrospinal fluid examination was not suggestive of meningitis, and a chest radiograph showed patchy infiltrates in the left lung field. Because neonatal sepsis was suspected he was commenced on intravenous cefotaxime and ampicillin pending the results of blood culture, which ultimately demonstrated no microbial growth.

On the 4th day of admission, marked jaundice was observed and the results of liver function tests and a coagulation profile were markedly deranged: total bilirubin (TB) 170 mmol/L (normal 5 - 21 mmol/L), conjugated bilirubin (CB) 98 mmol/L (normal 0 - 6 mmol/L), alanine aminotransferase (ALT) 1 880 U/L (normal 4 - 35 U/L), aspartate aminotransferase (AST) 3 424 U/L (normal 0 - 65 U/L), alkaline phosphatase (ALP) 1 481 U/L (normal 82 - 383 U/L), gamma-glutamyl transpeptidase (GGT) 145 U/L (normal 12 - 122 U/L), lactate dehydrogenase (LDH) 626 U/L (normal 180 - 430 U/L), ammonia 105 mmol/L (normal 40 - 80 mmol/L), international normalised ratio (INR) 8.7 (normal 2.0 - 3.0), prothrombin time (PT) 115.6 seconds (control 14.7 seconds), activated partial thromboplastin time (APTT) 119.3 seconds (control 30.0 - 40.0 seconds), fibrinogen 0.9 g/L (normal 2.0 - 4.0 g/L) and factor V 7.5% (normal 48 - 132%). He had microcytic anaemia, a sickle test was normal, and his C-reactive protein (CRP) level was 21 mg/dL (normal <10 mg/dL).

Further laboratory results were as follows: negative hepatitis A immunoglobulin M (IgM), low-positive HBsAg (signal close to the cut-off for the assay), positive hepatitis B surface antibody (anti-HBs) of 80.7 mIU/mL and negative hepatitis B core IgM. Hepatitis C antibody, hepatitis E IgM, herpes simplex virus 1 and 2 polymerase chain reaction (PCR), HIV DNA PCR, parvovirus B19 PCR, rubella IgM and *Treponema pallidum* antibody tests were negative. The cytomegalovirus VL was 730 IU/mL, the Epstein-Barr virus VL was lower than the detectable level, the thyroid-stimulating hormone level was 0.86 mIU/L (normal 0.72 - 11.0 mIU/L) and the thyroxine level was 21.2 pmol/L (normal 11.5 - 28.3 pmol/L). Galactosaemia and MPV17-related hepatocerebral mitochondrial DNA depletion syndrome were considered, but the common c.404C >T (p.5135L) and c.C106T (P.Q36X) mutations in the galactose-1-phosphate uridylyltransferase (*GALT*) and *MPV17* genes, respectively, were not detected. An abdominal ultrasound scan revealed a non-enlarged

liver with coarse echotexture. The mother tested positive for HBsAg and hepatitis B e antibody (anti-HBe), but was HBeAg-negative. Her HBV VL was detectable at 760 IU/mL.

The clinical manifestations together with the laboratory findings suggested a diagnosis of fulminant hepatic failure secondary to vertical HBV infection. Treatment included vitamin K, oral lactulose and N-acetylcysteine. The infant received lamivudine and his antibiotics were changed to piperacillin/tazobactam and amikacin. He remained critically ill, requiring several platelet, cryoprecipitate and fresh frozen plasma infusions, and continued to deteriorate, becoming hypoglycaemic on day 10 of admission.

Table 1 shows evolution of the HBV markers. Repeat liver function tests and a repeat coagulation profile on day 15 of admission showed persistent derangements, i.e. TB 369 mmol/L, CB 93 mmol/L, ALT 51 U/L, AST 55 U/L, ALP 3 227 U/L, GGT 32 U/L, LD 436 U/L, INR 7.54, PT 86.3 seconds (control 12.6 seconds), PTT 109.8 seconds (control 29.5 seconds) and fibrinogen 0.7 g/L (normal 2.0 - 4.0 g/L). The infant remained critically ill, his liver transaminases continued to decline, the coagulopathy persisted, the jaundice worsened, and he continued to experience hypoglycaemic spells. He subsequently developed melaena and grade II encephalopathy. He continued to deteriorate and died on day 45 of admission.

Genetic analysis of HBV from mother and infant

Total nucleic acid was extracted from serum samples of mother and infant using the MagNA Pure LC automated extraction method as per the manufacturer's instructions (Roche Diagnostics GmbH, Germany). For HBV genotype assignment, a semi-nested PCR was used to amplify a region of the surface and overlapping polymerase (*S/pol*) gene: primers P6F and P2R^[15] in the first round and P7F^[16] and P2R in the second. The PCR protocol from Smuts *et al.*^[17] was followed with minor modifications.

The basal core promoter (BCP), pre-core/core region (PC) was amplified using a nested PCR protocol.^[18] The entire surface antigen gene (preS1, preS2 and S) was amplified using primers and protocol from Chook *et al.*^[19]

Bidirectional Sanger sequencing of the *S/pol*, BCP/PC and S amplicons was performed using the BigDye terminator cycle sequencing kit (Applied Biosystems, USA). The HBV genotype was determined using the web-based geno2pheno program (<http://www.geno2pheno.org/index.php>).

To determine the heterogeneity of the BCP/PC and S genes, amplicons from both mother and infant were cloned into a pGEM-T vector according to the manufacturer's instructions (Promega Corp., USA). Multiple clones were subjected to Sanger sequencing and aligned using BioEdit version 7.2.6.1 (Softpedia, Romania).

Table 1. Plasma markers of HBV infection in mother and infant

HBV marker	Mother	Infant, day 4 of admission	Infant, day 17 of admission
HBsAg	Positive	Low positive	Negative
Anti-HBs (mIU/mL)	Negative	80	126
HB core IgM	Negative	Negative	Low positive (1.21 S/CO)
HB e antigen	Negative	ND*	ND*
Anti-HBe	Positive	ND	ND
HBV VL (IU/mL)	760	465	209
Hepatitis D PCR	ND	Negative	ND

HBV = hepatitis B virus; HBsAg = hepatitis B surface antigen; anti-HBs = hepatitis B surface antibody; IgM = immunoglobulin M; anti-HBe = hepatitis B e antibody; S/CO = signal/cut-off; ND = not done; VL = viral load; PCR = polymerase chain reaction.
*Insufficient sample available to perform e-antigen testing. Sequence analysis of infant's virus indicated the e-minus phenotype.

Discussion

We present this case because it highlights the need to improve HBV prophylaxis to infected mothers and their infants. The case is unusual because the mother was anti-HBe-positive and had a low VL, only 760 IU/mL, but still transmitted infection to her infant. Also, the infant developed a fulminant infection that led to his death. The commonest scenario associated with MTCT of HBV is when the mother is HBeAg-positive and has a high HBV VL (>6 log IU/mL). This was previously reported to be relatively uncommon in Africa and accounted for the decision to omit a birth dose of HBV vaccine from the infant immunisation schedule in SA. However, more recent studies have found that between 18% and 37% of HBV-positive pregnant women in SA are HBeAg-positive.^[9,10,20] Many HBV-positive individuals are co-infected with HIV, and this could influence the HBeAg status of infected individuals.

Was this MTCT?

Genetic analysis of the virus in mother and infant samples showed that both were infected with HBV genotype E. The mother was from the DRC, and genotype E is a predominant HBV genotype found in that country.^[1] Sequence analysis of the BCP/PC genomic region and the preS1, preS2 and S open reading frames (ORFs) of HBV revealed that the mother's and infant's viruses had multiple signatures in common, providing evidence that their infections were indeed epidemiologically linked. Common motifs included a near-identical deletion in the preS2 region (position 399 - 420 in the mother and position 402 - 420 in the infant), a 3-nucleotide insertion at position 598 - 600 in the small S ORF, and multiple single-nucleotide polymorphisms (Fig. 1, A and B).

The HBeAg-negative phenotype and its significance

HBV infection in infants and young children is usually associated with subclinical infection. Liver damage/hepatitis in HBV infection is immune mediated (due to cell-mediated immune attack on HBV-infected liver cells). The milder clinical illness in the very young has been attributed to the tolerising effect of HBeAg. This protein is a potent immune modulator and immune evasion molecule, acting at multiple levels to induce immune tolerance: it blocks cellular responses to type 1 and 3 interferons,^[21] interferes with toll-like receptor signalling and induces the expression of PD-1 (an exhaustion marker) on CD8+ cells, com-

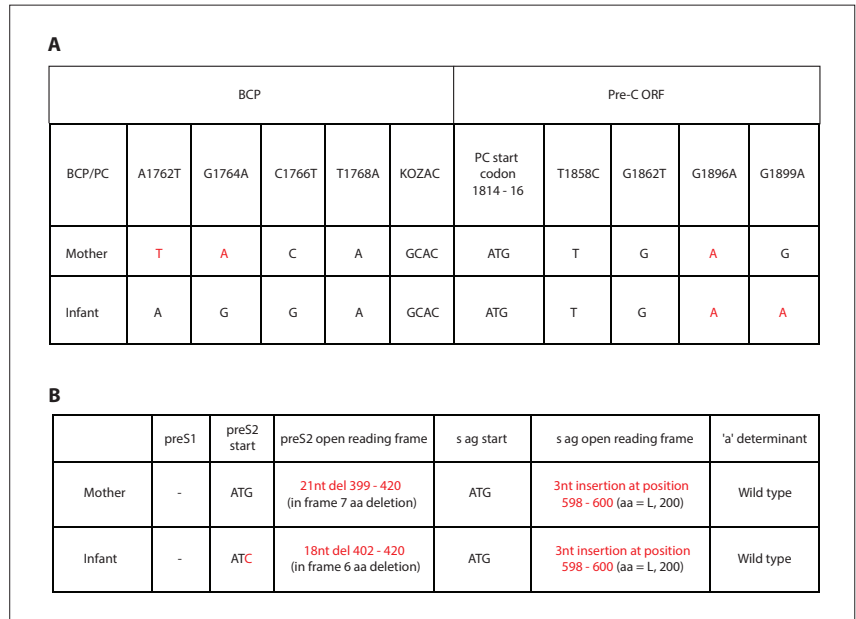


Fig. 1. Genetic features of HBV present in mother and infant blood. (A) Sequence analysis of the BCP and PC region revealed that immune escape mutations A1762T and G1764A were present in the mother's virus, but absent from the infant's virus. Both contained the G1896A mutation, which truncates the HBeAg protein and confers the e-minus phenotype. (B) In the preS/S genes, the preS2 start codon was mutated in the infant's virus, but intact in the mother's. Both had large deletions in the preS2 gene, and there was a 21nt deletion from 399 to 420 in the mother's virus and an 18nt deletion from 402 to 420 in the infant's virus. A 3nt insertion was present in the small S ORF in both the mother's and the infant's virus. The 'a' determinant was unchanged. (BCP = basal core promoter; Pre-C = pre-core; ORF = open reading frame; PC = pre-core/core; s Ag = surface antigen; nt = nucleotide; aa = amino acid. Mutations and deletions in the HBV genome in mother and infant blood are indicated in red.)

promising their antiviral activity.^[22] The effect of this is to attenuate the antiviral immune response (and severity of clinical hepatitis) and enable the virus to establish persistent infection in the host.

Both the mother's and the infant's virus had the common G1896A mutation in the BCP/PC region. This mutation is frequently selected for during the immune-active phase of chronic HBV infection and probably became the predominant species in the mother's blood years before. This mutation introduces a stop codon that truncates the HBeAg protein at the level of translation. In addition, the mother's virus had further mutations in the BCP region (1762T, 1764A), known to reduce the synthesis of the pre-C mRNA transcript from which the HBeAg is synthesised. Transmission of HBV lacking functional HBeAg prevents the establishment of chronic infection but predisposes to more severe clinical hepatitis (due to the vigorous immune attack on infected liver cells). The fact that HBsAg was negative in the second blood sample from the infant is evidence that he was indeed clearing the infection. In a study of infants infected with HBV through MTCT, HBeAg-negative status in mothers was more likely to be associated with

fulminant hepatitis in their infants, while infants of HBeAg-positive mothers were more likely to have mild hepatitis followed by chronic infection.^[12]

When did transmission happen?

MTCT of HBV can occur *in utero*, intra-partum or after birth (in breast-fed infants). As for HIV, the greatest risk of HBV transmission is during birth and this is when transmission probably occurred in this case.^[23] The infant received his first dose of HBV vaccine at 6 weeks of age and the second, just days before the clinical presentation, too late to prevent transmission. Viruses from breakthrough infections that occur in infants who have received HBV immunoglobulin or vaccine at birth frequently have mutations that alter the antigenicity of the major neutralising domain of the viral HBsAg, in the so-called 'a' determinant. Most common is a glycine-to-arginine change at amino acid position 145, first described by Carman *et al.*^[24] This mutation arises because the presence of neutralising antibody early on selects for viral variants with altered HBsAg protein that is not neutralised by the antibody. No changes were present in this region in either

the mother's or the infant's virus, suggesting that the infection was already well established before the first dose of vaccine.

Conclusion

While this is a rare complication of HBV infection, it highlights the fact that vertical infections in infants do occur in SA despite current prophylaxis. Most transmissions from HBeAg-positive mothers are probably missed, as the infants do not present with a typical clinical illness, and it is the rare fulminant presentations that draw attention. Current HBV prophylaxis in SA is out of step with current guidelines.^[14] Introduction of a birth dose of vaccine alone would improve efficacy, but given the prevalence of HBV infection among local pregnant women, we consider that prenatal screening is needed. Screening could be done at booking using a rapid test for HBsAg. The most cost-effective approach would be for women who test positive to receive tenofovir prophylaxis in the second to third trimesters. A small field study has already demonstrated the feasibility of this approach in the Western Cape Province.^[25] Also, the safety and acceptability of this drug has already been established for HIV-infected pregnant women.

Teaching points

- Mother-to-child HBV transmission may occur even when the maternal VL is low (<3 log IU/mL).
- Fulminant hepatitis in this infant was due to transmission of an HBV strain unable to express the e-antigen.
- This case provides evidence of failure of the current infant HBV prophylaxis programme in SA.

Acknowledgements. None.

Author contributions. DRH and SK conceived the study and wrote part of the article. OB, BE and RdL provided clinical management of the case and wrote the clinical part of the case report. HS performed molecular testing and analysis and gave input into writing the article.

Funding. None.

Conflicts of interest. None.

1. Kramvis A, Kew MC. Epidemiology of hepatitis B virus in Africa, its genotypes and clinical associations of genotypes. *Hepatology* 2007;37(s1):S9-S19. <https://doi.org/10.1111/j.1872-034X.2007.00098.x>
2. Dibisceglie AM, Kew MC, Dusheiko GM, et al. Prevalence of hepatitis B virus infection among black children in Soweto. *BMJ* 1986;292(6533):1440-1442. <https://doi.org/10.1136/bmj.292.6533.1440>
3. Botha JE, Dusheiko GM, Ritchie MJ, Mouton HWK, Kew MC. Hepatitis B virus carrier state in black children in Ovamboland: Role of perinatal and horizontal infection. *Lancet* 1984;323(8388):1210-1212. [https://doi.org/10.1016/S0140-6736\(84\)91694-5](https://doi.org/10.1016/S0140-6736(84)91694-5)

4. Abdoal Karim SS, Coovadia HM, Windsor IM, Thejpal R, van den Ende J, Fouche A. The prevalence and transmission of hepatitis B virus infection in urban, rural and institutionalized black children of Natal/KwaZulu, South Africa. *Int J Epidemiol* 1988;17(1):168-173. <https://doi.org/10.1093/ije/17.1.168>
5. Bhimma R, Coovadia HM, Adhikari M, Connolly CA. The impact of the hepatitis B virus vaccine on the incidence of hepatitis B virus-associated membranous nephropathy. *Arch Pediatr Adolesc Med* 2003;157(10):1025-1030. <https://doi.org/10.1001/archpedi.157.10.1025>
6. Tsebe KV, Burnett RJ, Hlungwani NP, Sibara MM, Venter PA, Mphahlele MJ. The first five years of universal hepatitis B vaccination in South Africa: Evidence for elimination of HBsAg carriage in under 5-year-olds. *Vaccine* 2001;19(28-29):3919-1326. [https://doi.org/10.1016/S0264-410X\(01\)00120-7](https://doi.org/10.1016/S0264-410X(01)00120-7)
7. Hoffmann CJ, Mashabela F, Cohn S, et al. Maternal hepatitis B and infant infection among pregnant women living with HIV in South Africa. *J Int AIDS Soc* 2014;17(1):1-5. <https://doi.org/10.7448/IAS.17.1.18871>
8. Chotun N, Nel E, Cotton MF, Preiser W, Andersson MI. Hepatitis B virus infection in HIV-exposed infants in the Western Cape, South Africa. *Vaccine* 2015;33(36):4618-4622. <https://doi.org/10.1016/j.vaccine.2015.06.076>
9. Diale Q, Pattinson R, Chokoe R, Masenyete L, Mayaphi S. Antenatal screening for hepatitis B virus in HIV-infected and uninfected pregnant women in the Tshwane district of South Africa. *S Afr Med J* 2016;106(1):97-100. <https://doi.org/10.7196/SAMJ.2016.v106i1.9932>
10. Thumbiran NV, Moodley D, Parboosing R, Moodley P. Hepatitis B and HIV co-infection in pregnant women: Indication for routine antenatal hepatitis B virus screening in a high HIV prevalence setting. *S Afr Med J* 2014;104(4):307-309. <https://doi.org/10.7196/SAMJ.7299>
11. Chen HL, Lin LH, Hu FC, et al. Effects of maternal screening and universal immunization to prevent mother-to-infant transmission of HBV. *Gastroenterology* 2012;142(4):773-781. <https://doi.org/10.1053/j.gastro.2011.12.035>
12. Tseng YR, Wu JF, Kong MS, et al. Infantile hepatitis B in immunized children: Risk for fulminant hepatitis and long-term outcomes. *PLoS One* 2014;9(11):1-8. <https://doi.org/10.1371/journal.pone.0111825>
13. World Health Organization. Hepatitis B vaccines: WHO position paper – July 2017. *Wkly Epidemiol Rec* 2017;92(27):369-392. <http://www.who.int/wer/2017/wer9227/en/> (accessed 11 April 2018).
14. Li J, Chang MS, Tran TT, Nguyen MH. Management of chronic hepatitis B in pregnancy. *J Clin Gastroenterol* 2017;51(9):1. <https://doi.org/10.1097/MCG.0000000000000908>
15. Liu BM, Li T, Xu J, et al. Characterization of potential antiviral resistance mutations in hepatitis B virus reverse transcriptase sequences in treatment-naïve Chinese patients. *Antiviral Res* 2010;85(3):512-519. <https://doi.org/10.1016/j.antiviral.2009.12.006>
16. Kew MC, Kramvis A, Yu MC, Arakawa K, Hodgkinson J. Increased hepatocarcinogenic potential of hepatitis B virus genotype A in Bantu-speaking sub-saharan Africans. *J Med Virol* 2005;75(4):513-521. <https://doi.org/10.1002/jmv.20311>
17. Smuts H, Sonderup M, Gogela N, Spearman CW. Hepatitis B virus genotype G: First report of complete genomic analysis from the African continent. *J Emerg Dis Virol* 2017;3(2). <https://doi.org/10.16966/2473-1846.130>
18. Makondo E, Bell TG, Kramvis A. Genotyping and molecular characterization of hepatitis B virus from human immunodeficiency virus-infected individuals in southern Africa. *PLoS One* 2012;7(9). <https://doi.org/10.1371/journal.pone.0046345>
19. Chook JB, Teo WL, Ngeow YF, Tee KK, Ng KP, Mohamed R. Universal primers for detection and sequencing of hepatitis B virus genomes across genotypes A to G. *J Clin Microbiol* 2015;53(6):1831-1835. <https://doi.org/10.1128/JCM.03449-14>
20. Andersson MI, Maponga TG, Ijaz S, et al. The epidemiology of hepatitis B virus infection in HIV-infected and HIV-uninfected pregnant women in the Western Cape, South Africa. *Vaccine* 2013;31(47):5579-5584. <https://doi.org/10.1016/j.vaccine.2013.08.028>
21. Yu Y, Wan P, Cao Y, et al. Hepatitis B virus e antigen activates the suppressor of cytokine signaling 2 to repress interferon action. *Sci Rep* 2017;7(1):1729. <https://doi.org/10.1038/s41598-017-01773-6>
22. Chen LM, Fan XG, Ma J, He B, Jiang YE. Molecular mechanisms of HBeAg in persistent HBV infection. *Hepatology* 2017;11(1):79-86. <https://doi.org/10.1007/s12072-016-9734-5>
23. Wen Y-M, Wang Y-X. Biological features of hepatitis B virus isolates from patients based on full-length genomic analysis. *Rev Med Virol* 2009;19(1):57-64. <https://doi.org/10.1002/rmv.600>
24. Carman WF, Karayiannis P, Waters J, et al. Vaccine-induced escape mutant of hepatitis B virus. *Lancet* 1990;336(8711):325-329. [https://doi.org/10.1016/0140-6736\(90\)91874-A](https://doi.org/10.1016/0140-6736(90)91874-A)
25. Chotun N, Preiser W, van Rensburg CJ, et al. Point-of-care screening for hepatitis B virus infection in pregnant women at an antenatal clinic: A South African experience. *PLoS One* 2017;12(7):1-11. <https://doi.org/10.1371/journal.pone.0181267>

Accepted 19 December 2017.