

# South African Medical Journal

## Suid-Afrikaanse Tydskrif vir Geneeskunde

P.O. Box 643, Cape Town

Posbus 643, Kaapstad

Cape Town, 22 December 1956  
Weekly 2s. 6d.

Vol. 30 No. 51

Kaapstad, 22 Desember 1956  
Weekliks 2s. 6d.

### A CASE OF ACUTE APPENDICITIS ASSOCIATED WITH A PREVIOUSLY UNDIAGNOSED URACHAL CYST

MICHAEL KATZEN, M.B., B.CH. (RAND), F.R.C.S. (EDIN.)

*Surgical Registrar, Transvaal Memorial Hospital for Children, Johannesburg*

Being unprepar'd,  
Our will became the servant to defect,  
Which else should free have wrought.

*Macbeth*

The acute abdomen is a 'Temple of Surprise', and it has been said that the potential appendicectomy should be prepared to cope with any acute abdominal emergency and should have in his repertoire the knowledge and experience of such major procedures as gastrectomy, cholecystectomy, resection of bowel and hysterectomy.

The following case-report illustrates a further eventuality which may be encountered during appendicectomy. As far as is known, no similar case has been reported in the literature.

#### CASE REPORT

A young girl, G. v. W., aged 11 years, was admitted to the Transvaal Memorial Hospital for Children on 25 September 1956. The history was one of pain in the right lower abdomen, starting suddenly 24 hours before admission. The pain was stabbing in nature, persistent, and with no area of radiation. The patient had vomited frequently since the onset of the pain and her bowels were regular. She had had no previous attacks of abdominal pain. With regard to micturition, there was no history of difficulty, frequency, burning or haematuria, and she had never been treated for any urinary complaint. The rest of the history was non-contributory.

Examination revealed a well-nourished patient with a flushed face, a temperature of 100°F and a pulse rate of 90 per min.

The pharynx was injected and the tonsils moderately enlarged. The tongue was dry and furred. The rest of the general examination was negative.

The abdomen was well covered with fat and moved poorly on respiration. Marked tenderness and moderate rigidity were felt in the right iliac fossa extending up to the umbilicus and just across the mid-line. There was a suggestion of fullness sub-umbilically, which was thought to be due to a full bladder. However, the patient stated that she had passed water 'an hour or two ago' and, when offered a bed-pan, was not able to pass water. Psoas and Rovsing's signs were positive and bowel sounds were normal.

A confident diagnosis was made of acute appendicitis, with early spreading peritonitis giving rise to the sub-umbilical tenderness and rigidity.

The operation was performed 1 hour after admission, under general anaesthesia. A right gridiron incision was made, with the skin incision transverse. On separating the internal oblique and transversus muscles, instead of coming onto peritoneum, one encountered the anterior wall of a tense, 'blue-domed', thin-walled cyst (Figs. 1 and 2 indicate the extent of the cyst). When an attempt was made to define the cyst further, it unexpectedly ruptured and out came 150-200 c.c. of urine!

The peritoneum was then opened and a gangrenous, retrocaecal appendix was removed easily in standard fashion. No free fluid or pus was found in the peritoneal cavity. The peritoneum was then closed with plain catgut after a stab drain had been placed down to the pouch of Douglas, since it was thought that some urine might have spilled into the peritoneal cavity.

The skin incision was next extended medially and the wound widened by incising vertically down the lateral border of the rectus sheath and retracting the rectus abdominis medially. The cyst was then traced extra-peritoneally down to the vertex of the bladder, with which it communicated through an opening admitting the tip of the little finger. No communication was noted between the cyst and the umbilicus.

The cyst wall was then cleanly excised and the bladder closed in 2 layers with plain catgut. A drain was placed down to the cave of Retzius through a further stab-incision and the wound then closed in layers with a wound drain down to the internal oblique muscle.

An indwelling urethral catheter was left in to drain the bladder and this drained blood-stained urine for 3 days after the operation. Fluids were given intravenously only for 2 days after operation and the patient received streptomycin and Crystacillin B.D. for 7 days. The catheter and the 3 drains were all removed on the 4th post-operative day and the patient was discharged from hospital 10 days after operation.

The cyst wall was sent for histological section and the report thereon read as follows:

'The specimen consisted of thin membranous tissue measuring approximately 3 by 1 cm.

'Sections of this specimen show the presence of a vascular connective tissue with a lining that varies from a multi-layered, modified type of pseudo-stratified epithelium to a flattened epithelium, with some parts lined only by a narrow band of very congested fibrous tissue. There is some smooth muscle present but this does not appear to be part of the cyst wall. The cyst wall consists largely of fibrous tissue with an occasional haphazard arrangement of a few smooth muscle bundles. This is not a true

diverticulum of bladder but could be consistent with a urachal cyst or a false diverticulum of bladder.

'The histological features and the age rather favour a urachal cyst than a diverticulum.'

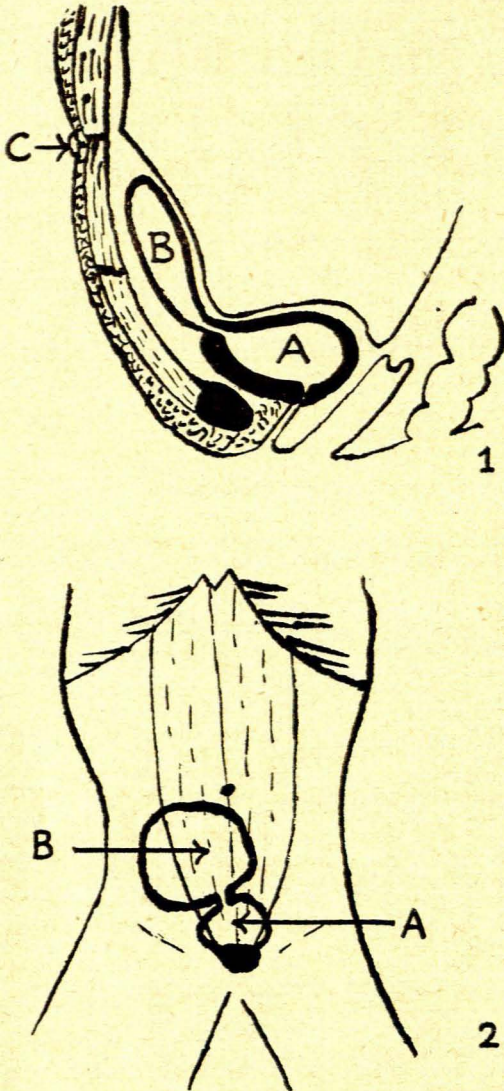


Fig. 1 (above) and Fig. 2 (below). Diagrams indicating the extent of the urachal cyst. Fig. 1—sagittal section. Fig. 2—coronal section. A—urinary bladder. B—urachal cyst. C—umbilicus.

#### DISCUSSION

Kantor (1939)<sup>1</sup> and Carreau and Higgins (1952)<sup>2</sup> review the literature on urachal cysts and deal adequately with their embryology, anatomy and physiology. Urachal cysts are conveniently divided into 4 types:

- (i). Those which communicate with the bladder.
- (ii). Those which communicate with the umbilicus.
- (iii). Those which communicate with the bladder and the umbilicus, forming a vesico-umbilical fistula.
- (iv). Those which do not seem to communicate with either.

The cyst mentioned in this case appears to belong to type I.

Urachal cysts commonly present as abdominal masses, and attention is usually drawn to them by recurrent infection occurring in them. They may also present with frequency of micturition or incontinence of urine.

Urachal cysts are notoriously difficult to excise because of adhesions due to recurrent infection, but this cyst-wall stripped particularly easily and no evidence of previous infection was noted.

The possibility that the cyst was, in fact, a simple diverticulum of the bladder has been considered, but one would have expected more smooth muscle in the wall and a continuation of vesical epithelial lining into the diverticular wall. Diverticula arising from the vertex of the bladder do occur in young children and are almost unknown in the absence of obstruction of the bladder outlet, e.g. in a male with posterior urethral valve obstruction or a 'pin-hole' meatus.

The diagnosis of urachal cyst was missed in this case. The diagnosis of appendicitis was quite obvious and the sub-umbilical resistance was thought to be due to spreading peritonitis; frankly, the diagnosis of urachal cyst was never entertained. Percussion of the abdomen was not performed because of the tenderness present and also because it is a test that is so often omitted in a 'classical appendix'—a lesson that I shall not forget easily.

What would have happened if the patient had been catheterized pre-operatively, thus emptying the cyst, can only be surmised. Perhaps the empty cyst might have been unwittingly incised during the opening of the peritoneum, with a resultant unexplained post-operative urinary fistula, or it might have been missed completely with a gridiron incision, to reappear as a mid-line swelling, causing a diagnostic headache for the surgeon at the follow-up clinic.

The reasons for publishing this case are, firstly, to report the very rare association of acute appendicitis and a previously undiagnosed urachal cyst and, secondly, to indicate that many a rude shock may await the too complacent surgeon while he is doing 'the usual appendix'.

#### SUMMARY

A case in a young girl of acute appendicitis associated with a urachal cyst is presented.

The cyst was discovered unexpectedly during appendicectomy.

This case illustrates a surprise that may await a surgeon while doing 'the usual appendix'.

For permission to publish this case, I am grateful to Mr. W. H. D. Trubshaw and Dr. K. F. Mills, Superintendent, Johannesburg General Hospital.

#### REFERENCES

1. Kantor, H. I. (1939): *Ann. Surg.*, **109**, 277.
2. Carreau, E. P. and Higgins, G. A. (1952): *Amer. J. Surg.*, **84**, 252.