

The Radiology of Renal Trauma

A LOCAL SURVEY

M. R. FUNSTON

SUMMARY

The main radiological features of the plain film of the abdomen, excretory urography and of renal angiography in 210 patients who had suffered renal trauma were reviewed. The role of excretory urography in these cases is examined and the need for renal angiography in all cases of renal trauma is discussed.

S. Afr. Med. J., 48, 981 (1974).

The clinical findings of shock, haematuria, tenderness or guarding in patients who have suffered an injury to the renal area, give little or no indication of the nature of the underlying kidney injury and the disruption of the renal anatomy. The degree of haematuria correlates poorly with the severity of renal injury. Patients presenting with profound haematuria can have minor trauma. On the other hand, cases presenting with minimal early clinical symptoms and signs may have severe late sequelae such as hypertension or massive retroperitoneal haemorrhage.

The plain radiograph of the abdomen, the excretory urogram and renal angiography, have become firmly established in the assessment of the nature of these underlying derangements. These investigations provide vital information to those who must decide on either conservative or surgical management, and, if the latter, what form of surgical procedure must be carried out.

An analysis of the main findings in patients referred for radiological examination is reviewed.

PATIENTS

During the period January 1969—June 1972, 210 patients were referred to the Department of Radiodiagnosis of the King Edward VIII Hospital following trauma to the kidneys. There were 132 males and 78 females. Of these, 96 cases were of penetrating injuries, 2 after bullet injury, and 94 after stab injury. Despite the fact that a number of percutaneous needle biopsies are performed in this hospital, no cases were referred for radiological investigation. There were 114 cases of non-penetrating injury, consisting of 61 cases involved in motor vehicle accidents, 44 cases of human blows, and 9 cases of falls.

Department of Radiodiagnosis, University of Natal and King Edward VIII Hospital, Durban

M. R. FUNSTON, M.B. B.CH., D.M.R.D. (Present address: Dept of Radiodiagnosis, Grootte Schuur Hospital, Cape Town)

Paper presented at the South African Radiological Congress held in Durban on 1-4 September 1972.

All 210 patients were investigated by excretory urography and a plain X-ray film of the abdomen. Retrograde pyelography was performed in 3 patients and renal angiography in 22. Of the 210 cases referred, abnormal radiological signs were observed in 112. All the radiological investigations were reviewed to assess the frequency of the various findings.

RESULTS

The Plain Film of the Abdomen

In most cases detail of abdominal organs and the psoas outline was obscured by faecal and gas shadows in the unprepared injured patient. Ileus resulting from renal trauma, with or without concomitant injury to other intra-abdominal organs, further obscured detail in a number of cases. A definite opinion on the presence or otherwise of obliteration of the psoas outline could thus only be given in 84 cases. Of these, 34 cases had definite obliteration of the psoas outline. Comment on the renal outline was only possible in 49 cases. The renal outline was lost in 15 cases, and was usually associated with a soft tissue mass. A definite fracture of the kidney with sharp disruption of the renal outline was seen in one case.

In 16 patients fractured ribs were observed. In 10 of these the fracture was a small slice fracture, varying from 5 to 40 mm in length, from either the superior or inferior margin of a rib (all were the result of stab wounds). Fractures of the lumbar transverse processes were observed in 15 patients. Scoliosis, concave to the injured side, was seen in 9 patients and renal emphysema in 1 patient.

The Excretory Urogram

The most common radiological finding was that of a localised decreased opacification of a calyceal group, seen in 64 patients. This could have resulted from localised renal contusion, intrarenal haematoma or an occlusion of the related infundibulum from blood clot or contusion.

The next most common finding observed (in 42 cases) was a 'spastic' pelvicalyceal system with a definite diminution of the intensity of the pyelogram. This results from poor urine flow due to decreased function. A suggestion of an intrarenal swelling (probably haematoma) was observed in 40 patients, and blood clot was seen in the collecting system in 36. The appearances varied from a small filling defect in a calyx to a complete blood 'cast'

of the calyces, pelvis, ureters and bladder. Extrarenal extravasation was observed in 32 patients, intrarenal extravasation in 27, and extravasation under the renal capsule in 14.

Displacement of the kidney, due to retroperitoneal haematoma, was seen in 18 patients. Enlargement of the kidney, due to intrarenal haematoma or oedema, was noted in 9 patients. A disruption of the cortical outline from a fracture of the cortex was observed in 4 patients and a localised decreased nephrographic stain (from infarction, contusion or haematoma) in another 4. Complete non-function was seen in 3 patients.

Evidence of obstructive uropathy from ureteric clot, compression of the ureter by retroperitoneal haematoma and from bladder clot retention, was noted in 18 patients. In 7 patients an underlying renal condition was noted incidentally.

Retrograde Pyelography

This examination was performed in only 3 patients. In one, intrarenal extravasation was confirmed, and in another a rounded swelling, ultimately shown to be a simple cyst, was demonstrated in a very poorly functioning kidney.

The third retrograde pyelogram was performed on a patient who presented with urinary non-function after trauma, and revealed gross bilateral hydronephrosis in association with a horse-shoe kidney. The patient died two days later and, at postmortem examination, the grossly

dilated pelvicalyceal system was seen to contain approximately 1 500 ml of blood.

Renal Angiography

This examination was performed in 22 patients after renal trauma. In 10 instances this was done within the first 12 hours after injury, in 8 patients within 24 hours, and in 4 within 4 days. Repeat renal angiography was performed twice, after further haematuria in the one instance and after surgical intervention in the other.

A localised decrease in the nephrographic stain, due to an intrarenal haematoma, laceration of the renal cortex, infarction, or siphoning from an arteriovenous fistula, was observed in 8 patients (Figs 1, 2 and 3). Three cases of arteriovenous fistulae were found, (Figs 1, 4 and 5), and 1 of traumatic aneurysm without arteriovenous shunting (Fig. 6). Intrarenal extravasation was noted in 3 patients (Fig. 6), a large parenchymal cleavage without devitalised margins in 2 (Figs 8 and 9), evidence of an intrarenal swelling (haematoma) in 2 and occlusion of a main branch vessel in 2 (Figs 7 and 8). Evidence of stretching and displacement of capsular arteries, due to a perinephric haematoma, was identifiable in one patient (Fig. 6). No cases of traumatic renal vein thrombosis, thrombotic occlusion of the main renal artery or avulsion of the renal vascular pedicle were noted.

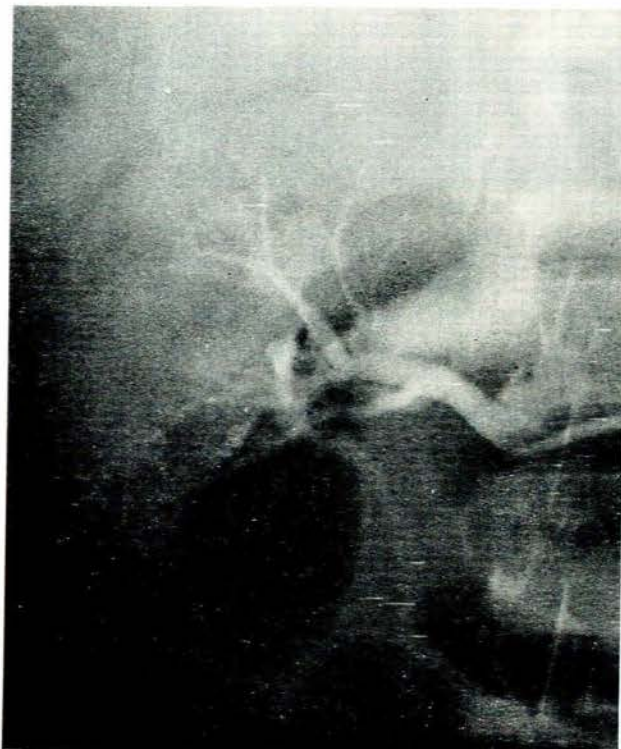


Fig. 1. Early filling of the renal vein is noted as a result of an arteriovenous fistula.

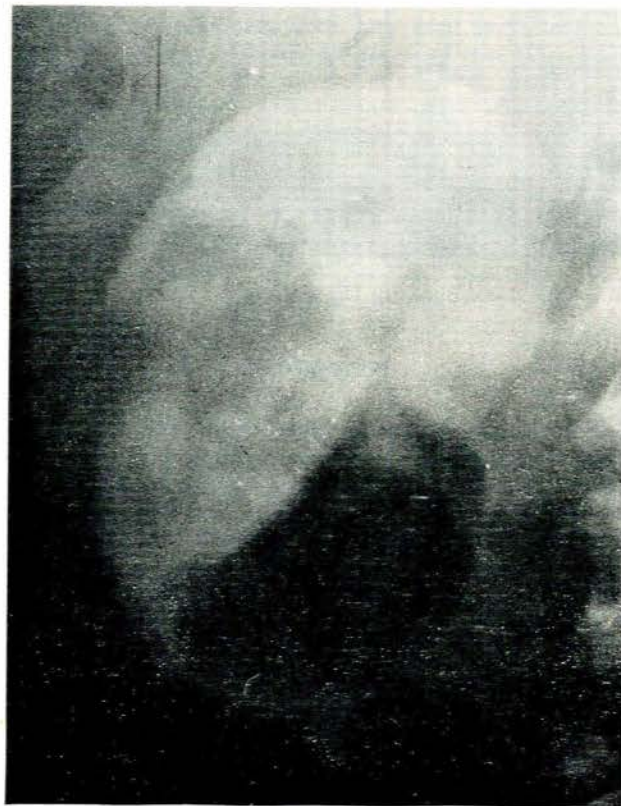

Fig. 2. Non-opacification of the mid-portion of the kidney due to siphoning by the arteriovenous fistula demonstrated in Fig. 1.

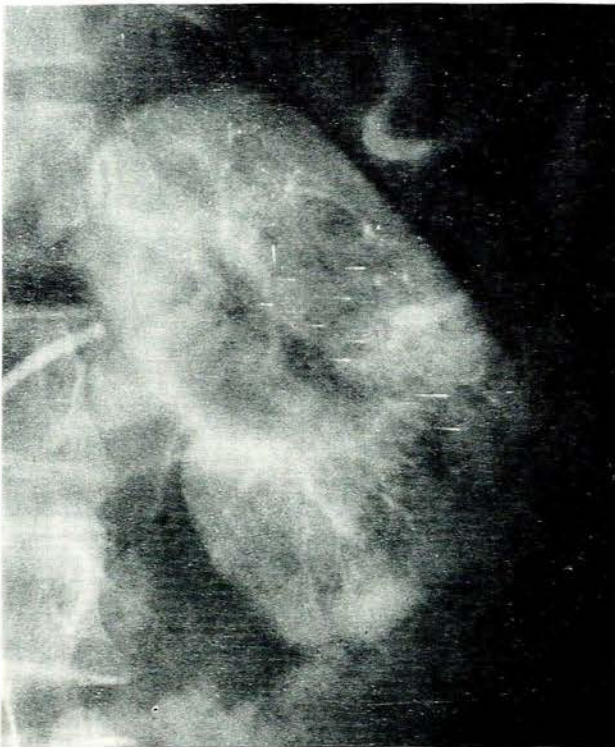


Fig. 3. There is a defect in the nephrogram of the lower pole of the left kidney from a cortical laceration.

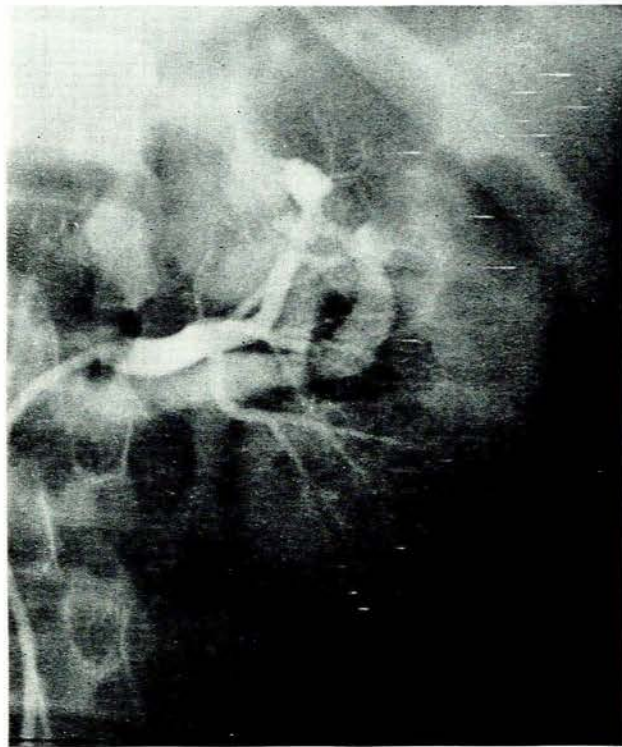


Fig. 5. An arteriovenous fistula is noted on the superior branch of the renal artery.

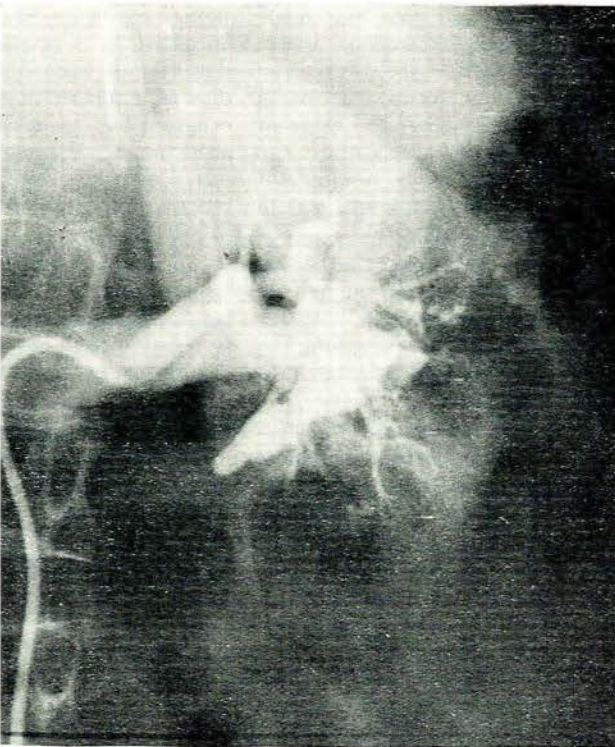


Fig. 4. A large arteriovenous aneurysm is noted.

Two patients in this series demonstrated abnormal angiographic findings with a definite normal excretory urogram in each case. In the first instance an angiogram was requested for persistent haematuria and a large arteriovenous fistula was demonstrated. In the second patient an occlusion of a branch artery with a segmental infarct was noted. Careful retrospective scrutiny of the excretory urograms, which were of good diagnostic quality, failed to show an abnormality.

In a further 2 patients, because of poor bowel preparation, the nephrogram of the excretory urogram was not adequately visualised. The pyelogram in each instance was normal. The angiogram of these cases revealed a localised decreased nephrographic stain, due possibly to either a small intrarenal haematoma, subsegmental infarct or an area of contusion.

DISCUSSION

In 19% of the cases a significant abnormality, in the nature of a definite loss of the psoas outline or of a large soft-tissue mass, was noted on the plain X-ray film of the abdomen. It is thus felt that this investigation is still of value in the radiological assessment of this form of injury.

In 53% of the cases referred for excretory urography a definite abnormal finding was identifiable. Since only 18 of these patients were investigated further by renal angiography, and because only 22 were ever explored surgically,

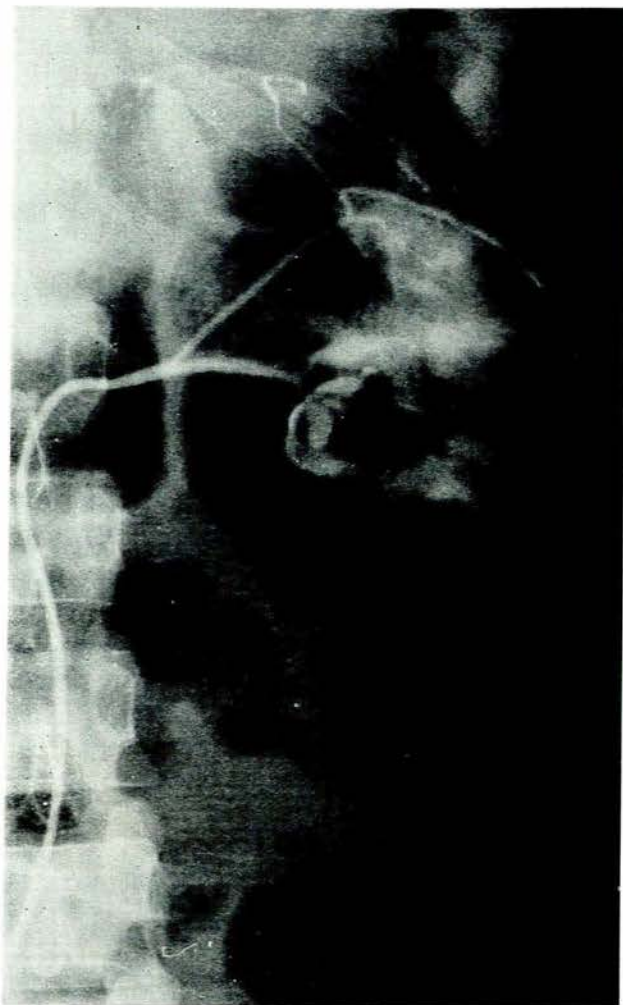


Fig. 6. A traumatic aneurysm without arteriovenous shunting is noted on the posterior branch of the renal artery. Intrarenal extravasation of contrast is present. There is marked stretching and lateral displacement of the capsular artery which arises from the posterior branch of the renal artery.

correlation of the excretory urographic findings and pathological-anatomical findings was poor. What is of interest, however, is that there were 4 instances where the excretory urographic findings were normal, and abnormalities were detected at subsequent renal angiography. Lang *et al.*,¹ correlating the excretory urographic findings and angiographic findings in their series of 68 patients, observed 68 abnormal arteriographic findings (some of which were often associated in the same patient). In 34 of these patients the excretory urograms were normal. These authors thus felt that immediate angiographic examination of all renal trauma patients was highly beneficial. They concluded that four types of injury—arteriovenous fistulae, traumatic aneurysm, renal infarction and loss of viability of the surrounding parenchyma—could only be assessed by renal angiography.

Elkin *et al.*,^{2,3} in their study of 29 consecutive cases

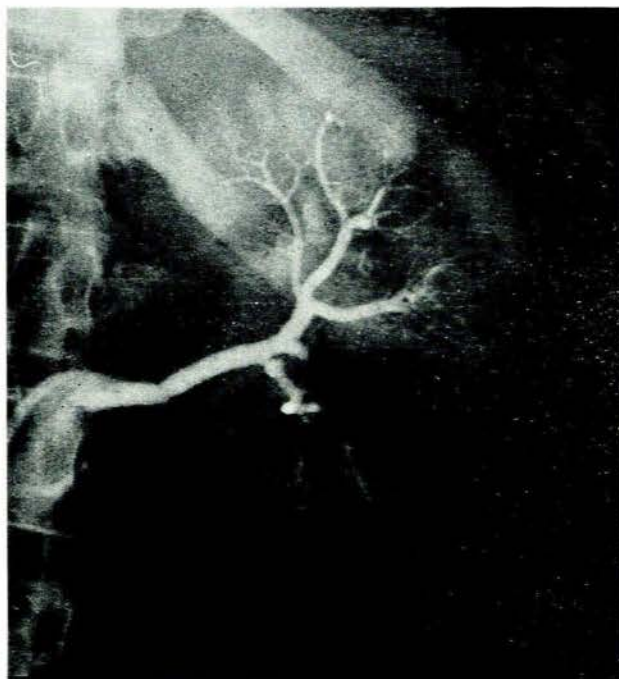


Fig. 7. There is an obstruction of the posterior branch of the renal artery with a spastic narrowing of the commencement of the inferior branch.

of suspected renal trauma by excretory urography and renal angiography, found that in 7 the excretory urogram was normal, and that the renal angiograms were also normal. The renal angiograms were negative in 5 of the 22 patients where the excretory urogram had been abnormal. In our series the angiogram was negative in 6 of the 18 cases where the excretory urogram had revealed an abnormality. These authors concluded that renal angiography is very likely not indicated in a patient with a normal excretory urogram, and that angiography will add no significant information in respect of the injury.

Lang *et al.*¹ observed that in only 15 out of 68 instances did the excretory urogram indicate the abnormality found at renal angiography. In our series angiography revealed an abnormality in 16 cases. The excretory urogram of these cases indicated the angiographic abnormality in only 6 cases.

From the observations in our series it would appear that renal angiography is indicated in all cases of suspected haematuria and that the excretory urogram findings do not correlate well with the angiographic findings.

Of the 210 patients, 8 were subjected to nephrectomy and 3 to partial nephrectomy, and in 10 the retroperitoneal space was explored without nephrectomy. In another case, where an arteriovenous fistula had been found on the posterior branch of the renal artery, with a resultant significant ischaemic area from siphoning, ligation of the affected branch was performed with no subsequent development of hypertension. It is suggested that, if renal angiography is performed more frequently in renal trauma, selective surgical procedures will become more frequent.

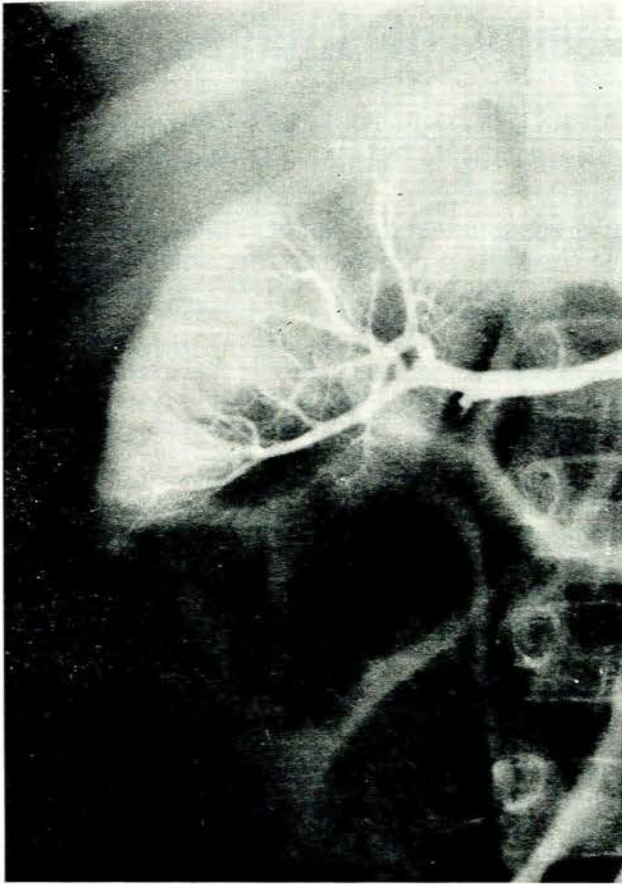


Fig. 8. There is a complete occlusion of the inferior branch of the renal artery. There is a large parenchymal cleavage of the upper pole.

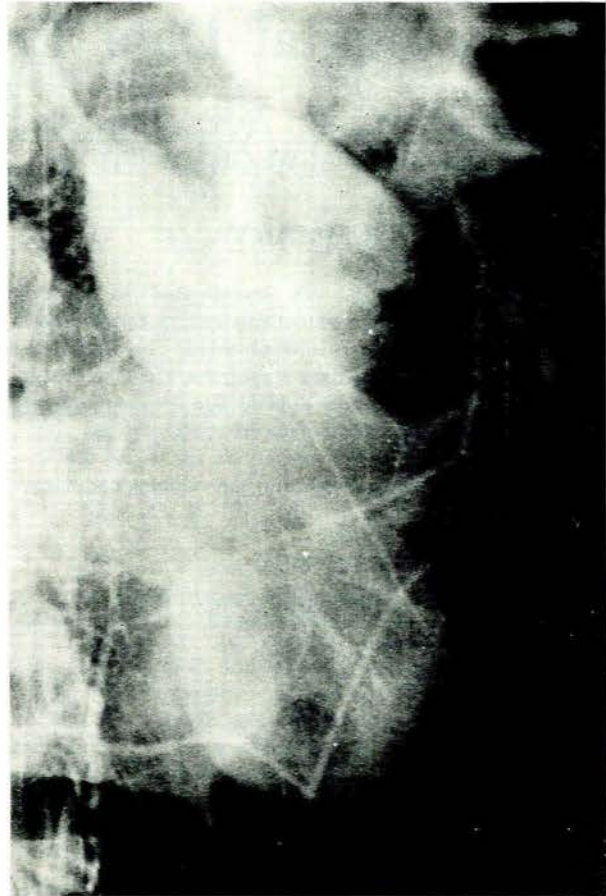


Fig. 9. There is a 'fracture' through the mid-portion of the left kidney with wide separation of the upper and lower poles.

Elkin *et al.*² classify the radiological findings at excretory urography into 3 groups.

Minor injuries are suggested by normal renal and psoas outlines, normal excretory urogram, or at the most minimal distortion of the calyces, diminished concentration of the contrast medium on the involved side, delayed excretion diminished excretory nephrogram and clots in the renal pelvis (61% of our patients fell into this group).

Major kidney injury is suggested by perirenal haematoma or extravasation of contrast medium, intrarenal or extrarenal (36% of the cases in our series).

In catastrophic injury there is marked deformity of the calyces, with loss of pelvic architecture and gross

extravasation of the contrast medium, or massive perirenal haemorrhage, or no excretion of contrast due to acute renal thrombosis or avulsion of the vascular pedicle of the kidney (3% of our cases).

I wish to thank the Department of Surgery of the University of Natal for their co-operation.

REFERENCES

1. Lang, E. K., Trichel, B. E., Turner, R. W., Fonfenot, R. A., Johnson, B. and St Martin, E. C. (1971): *Radiology*, **98**, 103.
2. Elkin, M., Meng, C. H. and De Pareden, R. G. (1966): *Ibid.*, **98**, 496.
3. *Idem* (1966): *Amer. J. Roentgenol.*, **98**, 1.