



CLINICAL IMAGES

Mediastinal mass, pneumonia or just plain normal?

Savvas Andronikou, Sanjay Prabhu, Joanna Kasznia-Brown, Russel Jones, David Grier, Lisa Goldsworthy

Increased density of an azygos lobe on chest radiographs may mimic a mediastinal mass. This may occur as a result of pneumonia or may be a variant of normal. Computed tomography (CT) scanning is indicated when a mediastinal mass is suspected in a child.

It is important to distinguish between airspace infection or collapse of the lung occurring adjacent to the mediastinum and a mass of the mediastinum. The former requires little follow-up while the latter requires cross-sectional imaging, and their treatment is different. It is also important to be aware of normal variants that may mimic disease and cause diagnostic confusion.

Case report

A 3-year-old boy presented with abdominal pain and fever. The investigation of an 'acute abdomen' included a chest radiograph. This revealed widening of the right side of the mediastinum with an outwardly convex margin and impression on the trachea (Fig. 1), which was interpreted as either lymphadenopathy or a mediastinal mass. The patient was treated empirically with amoxicillin. Follow-up radiographs 11 and 25 days later showed progressive decrease in size (Fig. 2) but it was thought prudent to exclude a mediastinal mass. A CT scan was performed to assess the mediastinum approximately 1 month after the initial presentation. This demonstrated parenchymal airspace

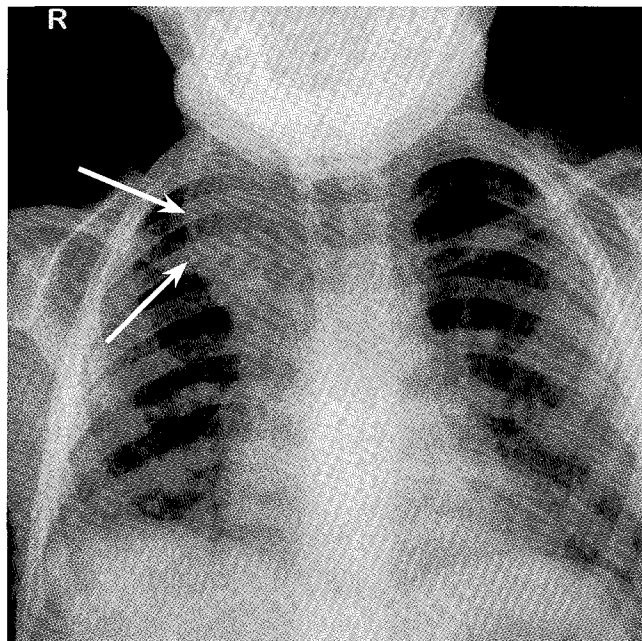


Fig. 1. Initial chest radiograph. A density adjacent to the trachea (arrows) merges with the mediastinum widening this structure. Tracheal impression suggests the presence of mediastinal mass.

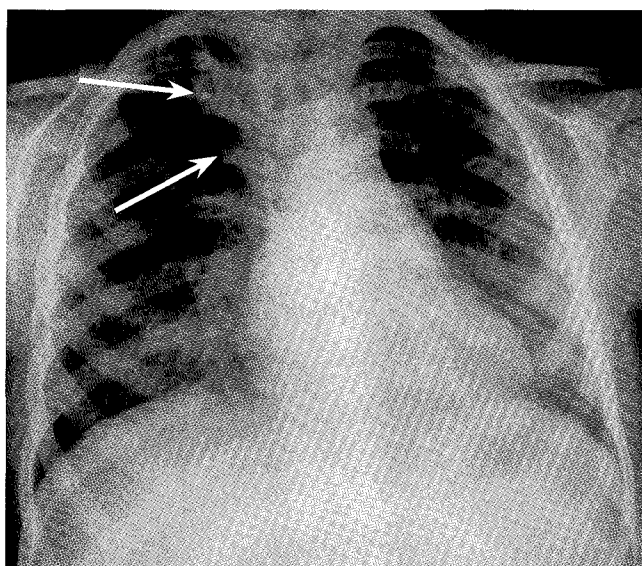


Fig. 2. Chest radiograph at 25 days. The right paratracheal density (arrows) has decreased in size but the appearance still suggests a mediastinal mass.

Savvas Andronikou is a Professor of Radiology at Stellenbosch University and Tygerberg Academic Hospital. He also holds a PhD, and is primarily involved in research relating to TB in children.

Sanjay Prabhu is a radiologist, currently on fellowship at Royal Children's Hospital in Melbourne, Australia.

Joanna Kasznia-Brown is a Registrar in Radiology on the Bristol (UK) training circuit.

Russel Jones is a part-time emergency medicine consultant at Bristol Children's Hospital and a full-time trapeze artist.

David Grier is a Consultant Paediatric Radiologist at Bristol Children's Hospital.

Lisa Goldsworthy is Head of Paediatric Emergency Medicine at Bristol Children's Hospital.



disease involving part of the azygos lobe bounded by the azygos fissure which extended from the medial aspect of the apex (Fig. 3,a). No mediastinal mass or lymphadenopathy was demonstrated (Fig. 3,b). The diagnosis was infective consolidation of the azygos lobe.

Discussion

Increased density of the azygos lobe on plain radiographs may be pathological or normal¹ and can cause diagnostic confusion prompting further investigation, as in our patient.

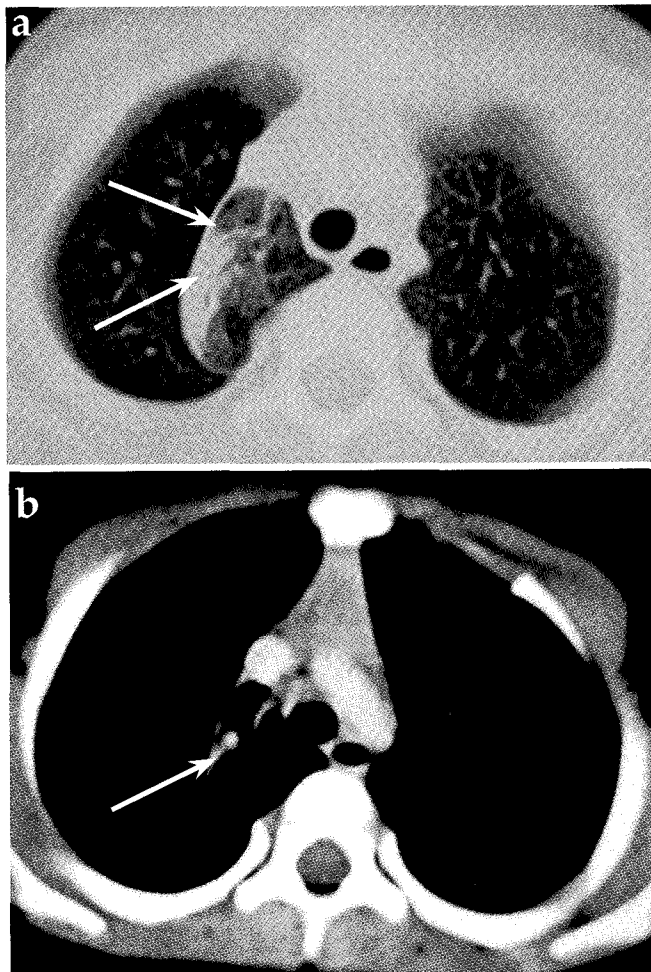


Fig 3.(a) CT scan: The airspace opacity (arrows) involving part of the azygos lobe is bound by the outwardly convex azygos fissure. (b) Mediastinal window demonstrates the azygos fissure extending from the superior vena cava anteriorly (arrow), but does not demonstrate any mediastinal mass.

A study found 7 of 53 azygos lobes reviewed retrospectively to be opaque. This was not the result of any pathological process, but increased soft tissue in front of the azygos lobe resulted in these appearances.¹ Another author² concluded that it is more likely that the width of the soft tissue in front of the azygos lobe was more important and was usually due to tortuous vessels occurring in older people. Stibbe's classification of the types of azygos lobe plays a role in these appearances. When the azygos fissure is located laterally, type A, it does not appear to cause any density.¹⁻³ Type B, with the fissure extending from the mid-apex, and type C with the fissure extending from the medial aspect, may appear opaque even when there is no pathology.^{1,3} In our patient the fissure corresponded with type C and resulted in a convex outer margin mimicking a mediastinal mass. The radiologist interpreted a 'widened mediastinum with an outwardly convex margin and impression on the right aspect of the trachea'.

Azygos lobe opacity is usually due to pathology,¹ especially in children, where the vessels of the mediastinum are not likely to be tortuous. CT scanning is useful when there is doubt.^{1,3} It helps to distinguish airspace pneumonia, right upper lobe collapse, neoplasm and mediastinal mass from normality.¹ On CT the azygos fissure is clearly visible and ends anteriorly at the right brachiocephalic vein/superior vena cava, and posteriorly at the lateral aspect of the vertebral body near the site of the right superior intercostal vein.³

Conclusion

Plain chest radiographs are the most common radiological investigation. Therefore the 0.4% of all radiographs that demonstrate an azygos lobe³ represent a significant number of the population. We must be aware of this normal variant when it is seen incidentally, but should also know that it may mimic disease by appearing opaque. Moreover, it is less likely that an opaque azygos lobe is normal in children because the vessels that cause this opacity in adults are not usually tortuous in children. CT is a good problem solver but awareness of this entity and correlation with the clinical findings may save the patient from the higher radiation burden and costs of CT scanning.

1. Caceres J, Mata JM, Alegret X, Palmer J, Franquet T. Increased density of the azygos lobe on frontal chest radiographs simulating disease: CT findings in seven patients. *Am J Roentgenol* 1993; **160**: 245-248.
2. Akan H. Cause of an opaque azygos lobe on frontal chest radiographs. *Am J Radiol* 1995; **164**: 510-511.
3. Mata J, Caceres J, Alegret X, Coscojuela E, De marcos JA. Imaging the azygos lobe: normal anatomy and variations. *Am J Roentgenol* 1991; **156**: 931-937.