

Case Report

Self-Surgery: Opening an Obstructed Inguinal Hernia

Nasir Mohd. H. Elsheikh*

Self-surgery is the act of performing a surgical procedure on oneself¹. It can be a rare manifestation of a psychological disorder, an attempt to avoid embarrassment or legal action, or an act taken in extreme circumstances out of necessity^{2,3}.

By far the most common type of self-surgery is orchiectomy, removal of one or both testicles⁴⁻⁶. A small number of males resort to self-surgery in an attempt to control their sexual urges or due to gender identity disorder⁷. Rarer still is the phenomenon of attempted repair of injury caused during masturbation or similar activity that would be embarrassing if revealed. One notable example of this is a case report by Morton (1991)^{8,9}. Abdominal self-surgery is extremely rare. A few well-publicized cases have found their way into the medical literature⁴.

We report here a very rare case of self-surgery presented as opened obstructed inguino-scrotal swelling in a 65 years old man. So we high light this unusual presentation of self-surgery

Keywords: self-surgery, inguinal hernia

A sixty seven years old man farmer presented to the casualty with eviscerated scrotal injury and pain. He admitted to have intentionally injured his swollen and painful scrotum.

On further history the patient mention that he have a swelling for the last six years it descend some times to his scrotum but reduce spontaneously when lying flat, but at the day of incident the swollen scrotum become very painful and he couldn't manage to reduce the swelling back. Fig. A&B

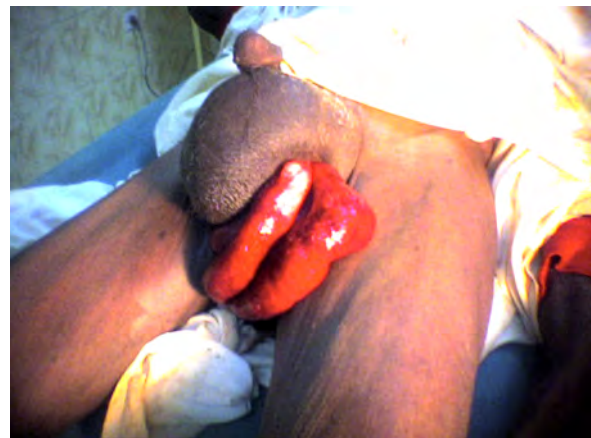When the pain became intolerable he took his knife and try to open his tens scrotum, so a part of his small bowel comes out.

The patient was brought to the hospital by his sons immediately after they sew his wound.

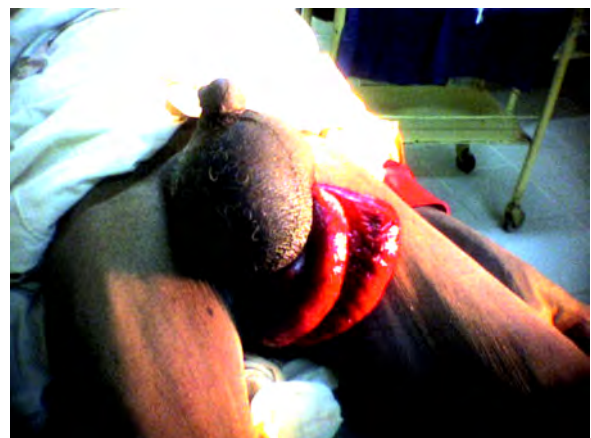
In the hospital the patient was resuscitated and pushed to the theatre and underwent a repair of his left indirect inguinal hernia .the bowel was found to be viable and washed thoroughly and place back to the abdominal cavity. The patient went through an uneventful postoperative period and discharged in a good condition

Till his last day in the hospital he didn't till about the real causes prevent him from seeking medical care before his self-surgery.

* Registrar of General Surgery. El Obied Teaching Hospital. Sudan. Correspondence to: nasirelsheikh@yahoo.com



A



B

Fig. A&B: The viable small bowel coming out the self induced incision.

Discussion:

Self-surgery is rare, but numerous cases of self-mutilation are reported in the literature (eg, castration, enucleation of an eye, and amputation of a limb)¹. We have found no previous reports in the literature of a patient who has performed self-surgery to relieve an obstructed inguinal hernia by opening his scrotum. The causes behind this self-mutilation is not well cleared but it seem that this old patient feel some stigma about his inguino-scrotal swelling .The patient lives in Elobied city where the health services is quite available and accessible , but still remain the question of its acceptability. .

References :

1. Tuke DH. *A Dictionary of Psychological Medicine*. Vol II. Philadelphia, Pa: Blackiston; 1982.
2. Kalin NH. Genital and abdominal self-surgery -- a case report. *JAMA*. 1979; 241:2188.
3. Winchel RM, Stanley M. Self-injurious behaviour: a review of the behavior and biology of self-mutilation. *Am J Psychiatry*. 1991;148:306-317.
4. Simeon D, Stanley B, Frances A, et al. Self-mutilation in personality disorders: psychological and biological correlates. *Am J Psychiatry*. 1992; 149:221-226.
5. Lowy FH and Kolivakis TL. Autocastration by a male transsexual. *Can Psychiatr Assoc J* 1971; 16:399-405.
6. Molina-Sosa A, Galvan-Espinosa H, Gabriel-Guzman J et al. Self-inflicted cesarean section with maternal and fetal survival. *Int J Gynecol Obstet* 2004; 84:287-290.
7. Money J and DePriest M. Three cases of genital self-surgery and their relationship to transsexualism. *J Sex Res* 1976; 12:283-294.
8. Money J. Genital self-surgery. *J Urol* 1980; 124:210.
9. Morton WA. Scrotum self-repair. *Med Aspects Human Sexuality* 1991:15.