



Peculiar epidermal peg pattern in cane rat skin

MO Akpan^{1*}, OM Samuel² & BO Emikpe³

1. Department of Veterinary Anatomy, University of Ibadan, Ibadan, Nigeria
2. Department of Veterinary Anatomy, Federal University of Agriculture Makurdi, Benue State, Nigeria
3. Department of Veterinary Pathology, University of Ibadan, Ibadan, Nigeria

*Correspondence: Tel.: +2348035737442; E-mail: apanobot@yahoo.com

Copyright: © 2020

Akpan *et al.* This is an open-access article published under the terms of the Creative Commons Attribution License which permits unrestricted use, distribution, and reproduction in any medium, provided the original author and source are credited.

Publication History:

Received: 07-09-2019

Accepted: 04-05-2020

Abstract

Skin is the largest organ in the body of man and animal where interdigitation of the dermal papillae with epidermal pegs enhances structural stability of the skin especially where frequent pressure is applied. Cane rats are robust rodents with stocky bodies. They are only found in Africa and only a single species known as *Thryonomys* has been found to exist. This work was designed to establish the nature of the interdigitating structural disposition of the epidermal-dermal interface in *T. swinderianus* (Greater cane rat) which may account for the fragility and easy tear of their skin. A total of twenty adult male greater cane rats were used. Three samples sized 1cm to 2cm were taken from each of 14 different body sites for histological evaluation for *rete pegs*. These pegs were generally few in six regions with the following average per light microscopic field: head (5.5±3.7), neck (1.0±1.7), forelimb (5.6±3.7), trunk (4.3±4.2), tail (1.0±1.7) and the hindlimb (6.3±5.3). The neck and the tail parts of the body have the least concentration of this structure compared to other regions evaluated. This few in number of *rete pegs* may account for the fragility of the skin which makes it difficult to restrain or handle without damage during research work procedures and management during domestication.

Keywords: Epidermal pegs, Fragility, Histology, Peculiar, *Thryonomys*

Introduction

The skin covers the body of man and animals and the internal body parts continuous with it via mucous membranes which include the buccal cavity, anus, and vulva (Slominski *et al.*, 2012). Grossly, the skin is the largest organ in the body and constitutes about 15% of the total body weight (Bologna *et al.*, 2008). The interface between the epidermis and the dermis is formed by raised ridges of the dermis, the dermal ridges (papillae), which interdigitate with invaginations of the epidermis called epidermal ridges or pegs. This predisposition enhances structural stability thereby preventing easy detachment of the skin from the underlying structures especially the hypodermis. Reinforcement

of the dermal-epidermal junction is ensured especially in skin subject to frequent pressure.

Cane rat is robust rodents whose body is covered with sharply pointed, but pliable hairs with coarse and brittle-like pelage (Plate 1). They have other names such as cane cutter, grasscutter, mast cane rat and groundhog (Abioye *et al.*, 2008). The family *Hystricomorpha* comprises the Hystricidae (family of the porcupines) and includes the *Thryonomys* (Grass cutters) also known as cane rat. They are found exclusively in Africa and described as the biggest of all African rodents (NRC, 1991) with stocky bodies, small ears, and long nails and are represented by a single species, *Thryonomys*. Most of its species, subspecies,

and breeds described may be allied to either: *T. swinderianus* (Greater grasscutter) or the *T. gregorianus* (the Lesser grasscutter) (Alogninouwa *et al.*, 1996). The thickest body measurement ranged from 40 to 60 cm in addition to 20-25 cm tail (Senou *et al.*, 1992). Body weight fluctuates between 2 and 4 kg and furs could be mixtures of brown, reddish and grey hairs that change with habitat. The species inhabits dense, reedy grassland with damp or wet places (Ajayi, 1971, Abioye *et al.*, 2008). Distribution of cane rats is determined basically by the availability of adequate or preferred grass species for food (Ajayi, 1971).



Plate I: Adult greater cane rats (*Thryonomys swinderianus*) in captivity

The greater cane rat is a semi-aquatic inhabitant whereas the lesser breed is found in the upland areas. Some work had been done on some aspects of cane rat to affirm that its existence is relevant to most areas of scientific research. For instance, Van der Merwe (2000) examined the growth rates of Greater cane rats on different diets to determine when to best market them. Studies had been carried out on the skull and mandible (Samuel *et al.*, 2015) and the brain (Slominski, 2012) and, Van Zyl *et al.* (2005) described the gross anatomy and histology of the alimentary tract of this rat. Research on the physiology of the digestive tract had also been documented (Alogninouwa *et al.*, 1996; Van Zyl & Delpont, 2010). Opara *et al.* (2006) had also reported a natural infection of both captive-reared and wild grasscutter with trypanosome species. Cane rat has been discovered to be very useful in scientific research (Opara *et al.*, 2006). However, the major challenge to its use is the fragility of the skin which makes it difficult to restrain or handle without damage during research work procedures. The possible scientific basis for this necessitated the study of the skin structure of cane rats. In the light of the foregoing, this study has been designed to closely study the epidermal-dermal interface whose predisposition might be responsible for the fragility and easy tear of the cane rat skin.

Materials and Methods

A total of twenty adult male cane rats were used. These rats were made to acclimatize for two weeks at the Faculty of Veterinary Medicine Experimental Animal Unit, University of Ibadan. Ethical approval

for the use of cane rats was obtained from the Animal Care Use and Research Ethics Committee of University of Ibadan UI-ACUREC/17/0026.

A total of 280 skin samples of size 1cm to 2cm were taken from 14 body sites namely: 1, Oral/ Nasal area; 2, Eye Region; 3, External ear area; 4, Neck region; 5 Upper forelimb; 6 Lower forelimb; 7, Digital (part); 8, Dorsum; 9, Lateral part of trunk; 10, Ventral part of trunk; 11, Upper hindlimb area; 12, Lower limb area; 13, Digital part and 14, Tail region (Plate II). Three samples were obtained from each site in each animal for histological evaluation of the *rete pegs*

These skin samples were taken using sample blades immediately after the animals had been deeply sedated by Ketamine (at 7mg/Kg body weight) and Xylazine (at 0.1mg/Kg body weight). The drugs used for sedation included Ketamine (Popular Pharmaceuticals Ltd. 164 Tongi Industrial Area, Gazipur-1171, Bangladesh) and Xylazine (V.M.D. n.v./s.a.-Hope Mauw 900- B2370 Arendonk, Belgium). Histological processing protocol described by Avwioro (2010) was used. The stain used during processing was Haematoxylin and Eosin (H & E) and photomicrographs were taken using a Leica DM LB2 microscope attached to a Leica ICC 50 E camera (Leica Microsystems, Wetzlar, Germany) with 5.0 ME resolution.

Results and Discussion

Generally, and histologically, the outer skin surface should be undulating with marked upward projections (dermal papillae) on some parts and depressions (epidermal ridges) on the other.

The epidermal ridges (interpapillary pegs) in cane rat skin were generally scanty or scarce in many areas of the body such as eye, ear, neck, forelimb, dorsal and lateral parts of the trunk and the hindlimb with the following numeric derivations per microscopic field as shown in Table 1.

Plate III also revealed the scanty *rete pegs* in photomicrographs of skin from the Eyelids, Ear, oral, Neck region, Dorsal trunk, Upper forelimb (forearms), Trunk lateral, Hindlimb (digital part) of cane rat skin.

Table 1: Epidermal pegs distribution in some body regions of cane rat skin

Body Region	Average Number of Epidermal Pegs per Field
Head	5.50 ± 3.7
Neck	1.00 ± 1.7
Forelimb	5.75 ± 3.7
Trunk	4.25 ± 4.2
Tail	1.00 ± 1.7
Hindlimb	6.25 ± 5.3

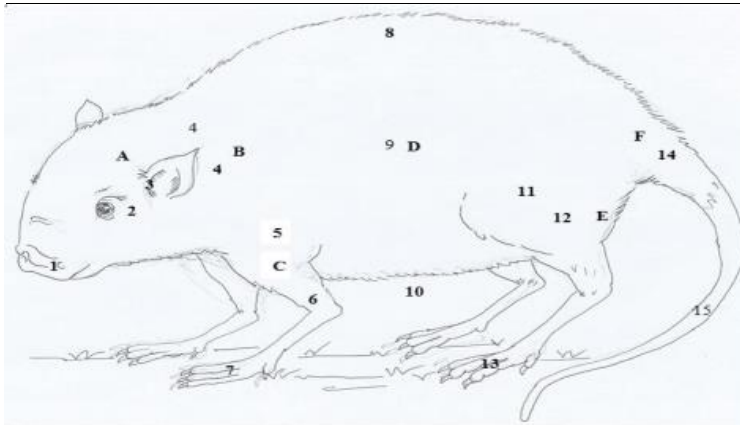


Plate II: Diagram of Body Regions Sampled. A Head region:

A. 1. Oral/ Nasal area. 2. Eye Region. 3. External ear area. B. 4. Neck region. C. Forelimb region: 5. Upper forelimb. 6. Lower forelimb. 7. Digital (part). D. Trunk: 8. Dorsum. 9. Lateral part of trunk. 10. Ventral part of trunk. E. Hind limb region: 11. Upper limb area. 12. Lower limb area. 13. Digital part. F. 14. Tail region (origin)

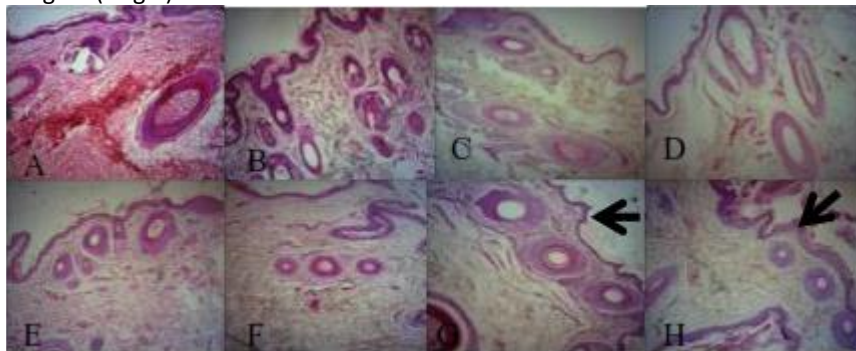


Plate III: Photomicrographs of skin of the (A) Eye, (B) Ear, (C) Oral area, (D) Neck region, (E) Dorsal trunk, (F) Upper forelimb (humerus part), (G) Trunk (lateral part), (H) Hindlimb (digital part) of cane rat skin showing scanty epidermal pegs (arrows). H&E X100

In most skin, the dermal-epidermal junction is not flat but rather conforms to a series of three-dimensional rete ridges and papillary projections of the dermis, ranging 50–400 µm in width and 50–200 µm in depth. This provides structural integrity to the skin and defines the cellular microenvironments critical for the proper functioning of the basal and suprabasal keratinocytes located in these regions (Bush & Pin, 2012).

In the Greater cane rat, the thickest epidermis that exists in the tail region would have been an added advantage to prevent it from easy damage during restraint or handling but the structural challenge of inadequate or scanty epidermal pegs makes the skin easily pre-disposed to damage.

In most animals, the dermis interdigitates with the epidermis so that upward projections of the dermis, the dermal papillae, interlock with the downward ridges of the epidermis, the *rete pegs* (Weiss & Greep, 1977).

This is important in the adhesion between epidermis and dermis as it increases the area of contact between them. In cane rat skin, the epidermal pegs were generally absent in some of the regions which included the head region (eye area), shoulder and tail regions. This feature renders the cane rat skin to be very fragile allowing it to break easily during handling or restraint.

As shown in Table 1 above, generally, the epidermal pegs are inadequate per body region of the cane rat skin. The neck and the tail parts of the body have the least concentration of this structure compared to other regions evaluated. The present work on histology of cane rat skin has shown that the tail of this rodent easily breaks off during restraint or handling. The higher numbers of epidermal pegs in shoulder, forelimb and hind limb further corroborate

the work of Bush & Pins (2012) where they opined that areas of the body that are subject to excess shear stress or friction, such as the palms of the hands and the soles of the feet, contain numerous narrow and deep rete ridges.

In conclusion, this communication showed that the scantiness of epidermal pegs in the skin of cane rats may account for the fragility of the skin which makes it difficult to restrain or handle without damage during research work procedures.

Conflicts of Interest

The authors declare no conflict of interest.

References

- Abioye FO, Udah AC, Opara MN, Onyema AC & Aju PC (2008). Adaptability Study of Grasscutter (*Thryonomys swinderianus*) in natural and Domestic Environments. *Proceeding of the Conference of Forestry Association of Nigeria held in Uyo, Akwa Ibom state Nigeria*. Pp 155–159.
- Ajayi SS (1971). Wildlife as a source of protein in Nigeria, some priorities of development. *The Nigerian Field*, **36**(3): 115–127.
- Alogninouwa T, Agba KC, Agossou E & Kpodekon M (1996). Anatomical, histological and functional specificities of the digestive tract in the male grasscutter (*Thryonomys swinderianus*, Temminck). *Anatomia, Histologia, Embryologia*. **25**(1): 15-21.
- Avwioro OG (2010). Hematoxylin and Eosin for General Tissue Structure. *Histochemistry and Tissue Pathology; Principles and Techniques*, second edition edition University Press, Delta State University. Abraka, Nigeria. Pp 28-46.
- Bolognia JL, Jorizzo JL & Rapini RP (2008). *Dermatology*. Second edition. St Louis, MO: Mosby Elsevier, London, England. Pp 103-114.
- Bush KA & Pins GD (2012). Development of Microfabricated Dermal Epidermal Regenerative Matrices to Evaluate the Role of Cellular Microenvironments on Epidermal Morphogenesis Tissue Engineering Part A. doi: 10.1089/ten.tea.2011.0479.
- NRC (1991). *Microlivestock; Little Known Small Animals with a Promising Economic Future*. National Research Council, National Academy Press, Washington DC, USA. Pp 449.
- Opara MN, Ike KA & Okoli IC (2006). Haematology and Plasma Biochemistry of the Wild Adult African Grasscutter (*Thryonomys swinderianus* Temminck). *The Journal of American Science* **2**(2): 17-22.
- Samuel OM, Parés-Casanova PM, Nwaogu IC & Olopade JO (2015). Morphometrics of the skull of two African rodents, *Thryonomys swinderianus* and *Cricetomys gambianus*. *Annals of Experimental Biology*, **3**(2): 21–30.
- Senou M, Yawadan LT & Schrage RC (1992). Contribution to Genetic Improvement of Grasscutter (*Thryonomys swinderianus*). Cotonou, Benin. In: *Proceedings of First Conference on Grasscutter Production*. Pp 175–85.
- Slominski AT, Zmijewski MA, Skobowiat C., Zbytek B, Slominski RM & Steketeet JD (2012). Sensing the environment: regulation of local and global homeostasis by the skin and neuroendocrine system. *Advanced Anatomy, Embryology and Cell Biology*, doi: 10.1007/978-3-642-19683-6_1.
- Van der Merwe M (2000). Tooth Succession in the Greater Cane Rat (*Thryonomys swinderianus* Temminck, 1827). *Journal of Zoology (London)*, doi.org/10.1111/j.1469-7998.2000.tb00811.x.
- Van Zyl A & Delpont JH (2010). Digestibility of the nutrients and aspects of the digestive physiology of the greater cane rat, (*Thryonomys swinderianus*), in two seasons. *African Zoology*, **45**(3): 254-264.
- Van Zyl A, Rambau RV & Van Der Merwe M. (2005). Aspects of the anatomy and histology of the alimentary canal of the greater cane rat, *Thryonomys swinderianus*, with reference to its feeding physiology. *African Zoology*. **40**(1): 25-36.
- Weiss L & Greep RO (1977). *A Textbook of Histology*, fourth edition. Pp 605-608.