



## Gastric diverticulosis and ulcerations in bitches

EO Abidoeye<sup>1\*</sup>, M Abdurrahman<sup>1</sup>, EG Emmanuel<sup>2</sup>, M Lawal<sup>1</sup>, BD Remi-Adewunmi<sup>1</sup>  
& AZ Hassan<sup>1</sup>

1. Department of Veterinary Surgery and Radiology, Ahmadu Bello University, Zaria-Nigeria

2. Veterinary Teaching Hospital, Ahmadu Bello University, Zaria-Nigeria

\*Correspondence: Tel.: 2348036347603, E-mail: doctorebe@yahoo.com

### Abstract

Two bitches were presented to the Small Animal Clinic Unit of the Ahmadu Bello University Veterinary Teaching Hospital Zaria, Nigeria with clinical manifestation suggestive of gastric diverticulosis and ulcer. The cases were confirmed through contrast radiography (using barium meal), hemogram, and ultrasonography. Management was effected using gastropasty resulting in complete recovery from the initial clinical presentation.

**Keywords:** Canine, Contrast radiography, Pyloroplasty, Gastric diverticulosis, Ulcerations.

Received: 08-05-2013

Accepted: 08-01-2014

### Introduction

Gastric diverticula are pouch-like herniations found on the stomach wall which occasionally could be asymptotically or manifest signs of gastrointestinal disorders (Ciftci *et al.*, 1998). Diverticula could be classified as congenital or acquired, true (full thickness) or false (mucosal), primary or secondary and intraluminal or extraluminal (Rashid *et al.*, 2012). This condition is very rare conditionally found in the canine species (Van Klaveren *et al.*, 2008) and this is the first report of this condition in canine species in Nigeria.

Gastric diverticula in humans were first described in 1661 by Moebius and in 1774 by Roax (Moses, 1946). In human it was first reported in Nigeria in 2008 (Olokoba, *et al.*, 2008). True gastric diverticula in the stomach of hogs and humans were reported earlier (Keith, 1910; Louis & Morris, 1936). Marshall and Hayes (1966) were the first to report Meckel's diverticulum in dogs, where they described it as a remnant of the vitelline duct connecting the embryonic midgut to the yolk sac and this normally atrophies when placental nutrition replaces the yolk sac (Van Klaveren *et al.*, 2008).

True gastric diverticula may occur at any age though middle age individuals are more prone to the disease. Often the incidence of gastric diverticulum is evenly distributed between male and female in

human (Rashid *et al.*, 2012). A large percentage of gastric diverticula are asymptomatic and because of this, its management is associated with the management of the disease process ongoing while the condition is detected and then followed up conservatively (McKay, 2005).

### Case history

#### Case 1

An 18 month old Alsatian bitch was presented to the Small Animal Unit of the Ahmadu Bello University Veterinary Teaching Hospital (ABUVTH) Zaria, Nigeria with complaints of anorexia and persistent vomiting especially after meals. History also revealed that the dog had been treated for canine parvovirus enteritis two weeks prior to presentation. The clinical signs noticed were melena, persistent emesis observed often between 20-30 minutes after meals, reduced appetite, pale mucus membrane, lethargy and the vital parameter were as seen in table 1. Hematological samples revealed anaemia, Leucocytosis due to neutrophilia as well as proteinuria (Table 2). Urine samples analyzed using "combi 10 kit" showed proteinuria and negative glucosuria. Contrast radiographs using barium meal indicated a diverticular pouch (Plate I). Further fecal and blood sample investigations indicated negative results for oocytes and parasites.

**Case 2**

A two-year-old female Terrier cross was referred to the Small Animal Clinic of Ahmadu Bello University Veterinary Teaching Hospital (ABUVTH), with the history of organophosphate poisoning which had been treated *abs initio*. Upon presentation, the vital parameter was as shown (Table 1). The problems included emesis 15 -20 minutes after the ingestion of a heavy meal, weight loss, reduced appetite, pallor and lethargy. The referring clinician had managed the condition with intravenous administration of Darrow’s solution and atropine sulphate at 0.05 mg/kg bid 3/7 intramuscularly. The concentration of the atropine sulphate used by the initial clinician was not specified.

Contrast radiography revealed a pear shaped pouch-like blind-ending sac (diverticulum) on the stomach wall with a stricture in between the sac and the fundus of the stomach. There were also irregular craters surrounding some pits, present on the mucosal walls which were consistent with ulcerations. Abdominal ultrasonographic examination (frequency 7.5MHz) carried out was not diagnostic; hematologic report showed anaemia, leucocytocytosis due to neutrophilia and mild proteinaemia (Table 2). Parasitologic examination of the feces and blood indicated negative for oocytes and parasites.

**Management**

*Surgical*

Intravenous catheterization was done for the patient for pre and intra operative administration of normal

saline and drug administration. Tramadol (visicol<sup>®</sup>) was administered at 20mg/kg deep IM as preemptive analgesia. The dogs were restrained by the administration of preanaesthetic agents (Chlorpromazine by Dana at 4mg/kg IV and atropine (amopin<sup>®</sup>) at 0.05mg/kg IV), anaesthesia was by the administration of propofol (profol<sup>®</sup>) at 6mg/kg intravenously and maintained with the same agent via the indwelling intravenous catheter. The dogs were aseptically prepared by shaving, cleansing and draped. A cranial ventral midline abdominal incision was made and progressed to the peritoneum. Once the stomach was identified, the fulciform ligament was transected and at the point of the diverticulum, two stay sutures were made to exteriorize the stomach and a snipe biopsy was taken from the ulcerative site (Plate II and III) for histopathologic examination. A Y-U gastroplasty was carried out on the diverticula duct. The abdominal incision was then routinely closed in a three layer closure.

*Post-operative/ medical care*

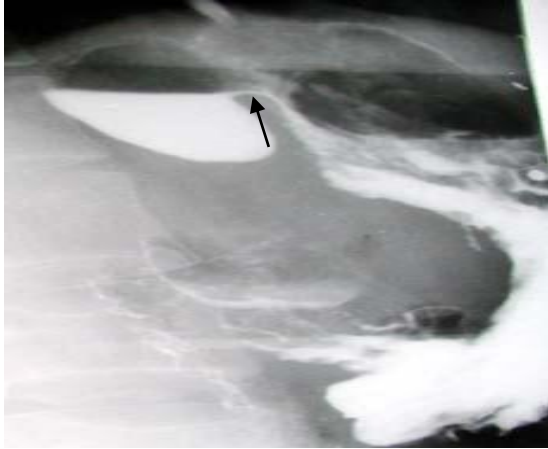The dogs were placed on metronidazole intravenous infusion at a dose of 12 mg/kg, for three days thereafter, 0.7 mg/kg once daily oral administration of omeprazole was given for two weeks. The wound was dressed every other day for 10 days while the surgical stitches was removed on the 8<sup>th</sup> day post-surgery. The dogs had returned to normal body function as at the second month after the surgery.

**Table 1:** Physical examination of the patient

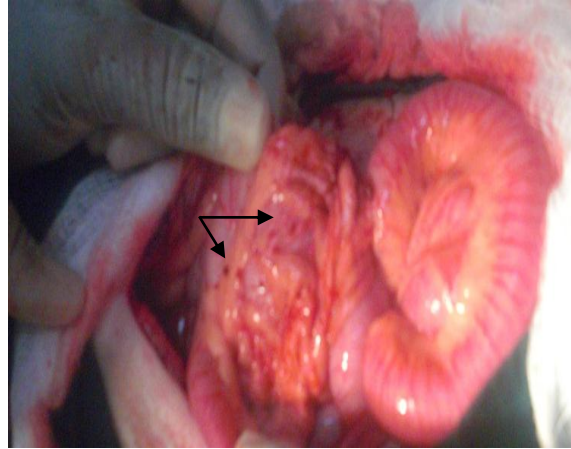
Vital parameters	Case1	Case2	Normal
Temperature (°C)	39.0	38.8	38.4- 39.4
Pulse rate (beat/min)	85	88	65-90
Respiratory rate (Cycles/min)	25	43	15-30

**Table 2:** Hematologic result for the cases reported

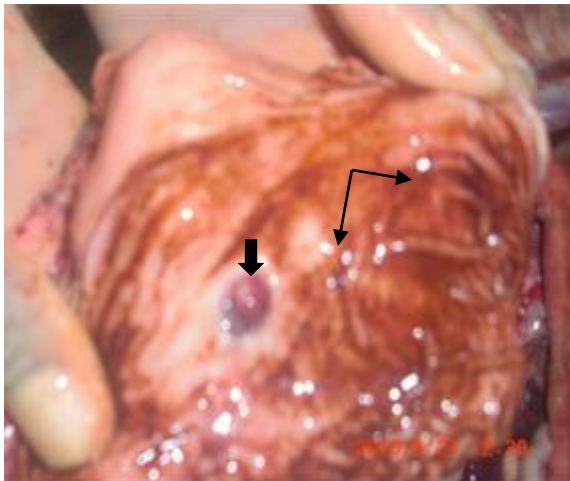
Parameters	Case1	Case2	Normal
Hb (g/dl)	8.6	7.3	12 -18
PCV (%)	25	22	37-55
WBC ( x 10 <sup>9</sup> /L)	8.4	25.7	6 -17
Neutrophils (x 10 <sup>9</sup> /L)	14.47	18.25	3.60 -13.09
Lymphocytes (x 10 <sup>9</sup> /L)	1.93	3.83	0.72- 5.10
Basophils (x 10 <sup>9</sup> /L)	3	0	Rare
Eosinnophils (x 10 <sup>9</sup> /L)	0.0	0.3	0.12- 1.70
Monocytes (x 10 <sup>9</sup> /L)	0.0	0.7	0.18 – 1.70
Total Proteins (g/dl)	6.0	5.2	5.4-7.7



**Plate I:** Single contrast barium meal of the abdomen of the bitch 40 minutes post ingestion of the contrast agent. Note the diverticulum: arrow.



**Plate II:** Intra-surgical photograph of the stomach diverticulum in-situ. Note the petechial hemorrhages (arrow).



**Plate III:** Intra-surgical photograph of the stomach exposing the hemorrhages (arrow) and the orifice of the diverticulum (arrow head)

### Discussion

Canine intestinal diverticulum had been reported in some earlier reports (Copper, 2002; Van Klaveren *et al.*, 2008). However, incidence of canine gastric diverticulum is an extremely rare condition in the canine species. The clinical signs of mild anaemia and persistent vomiting observed were likely caused by anorexia and stasis of food and foreign material, fermentation and subsequent mucosal irritation, diverticulitis and rupture of superficial blood vessels were due to the secondary conditions that were noticed in the dog (Van Klaveren *et al.*, 2008). Hemorrhage is the most frequent complication and occasionally there may be severe instances in which

true diverticula of the stomach have perforated. This complication, however, is extremely uncommon (Moses, 1946).

The unilocular pear-shaped pouch-like appearance of the diverticula which had an attendant small with narrow orifices and retention of some gastric contents that were observed identified the diverticula seen in this report as acquired gastric diverticulum (Plate I, III) due to secondary pathology to the stomach and these agreed with earlier report (Rashid *et al.*, 2012). True gastric diverticula are usually unilocular as was noticed in this case (Olokoba *et al.*, 2008). However, cases of

multilocular gastric diverticula have been reported (Gockel *et al.*, 2004).

The cases of symptomatic gastric diverticula can be treated medically (Kubiak & Hamill, 2006). In the cases where symptoms are evident, such as serious hemorrhage, impending perforations, or associated gastric ulcer, medical treatment should be tried as in the case we handled (Knoefel & Rattner, 2001). A bland diet with antacids and antispasmodics will often relieve the symptoms. Surgical extirpation of the diverticulum is indicated if the symptoms are severe and do not respond to mentioned medical measures. Furthermore, the occurrence of massive hemorrhage and the uncertainty of the presence of

other gastric abnormalities (particularly gastric ulceration, either benign or malignant) are definite indications for surgery (Kubiak & Hamill, 2006).

The surgical reconstructive management procedure that was performed in this report in which a Y-U gastroplasty was performed was similar to that of Johanna (2002) where a 1-year-old neutered male West highland terrier that had small intestinal diverticulum was corrected. Other surgical approaches had been mentioned such as excision of the diverticulum (Elliott *et al.*, 2006) or the use of resectioning of the diverticulum (Donkervoort *et al.*, 2006).

### References

- Ciftci AO, Tanyel FC & Hiçsönmez A (1998). Gastric diverticulum: An uncommon cause of abdominal pain in a 12 year old. *Journal of Pediatric Surgery*, **33**(3): 529-531.
- Cooper JC (2002). An endodermal cyst: the result of a congenital intestinal malformation. *Canadian Veterinary Journal*. **43**(9): 712-714
- Donkervoort SC, Baak LC, Blaauwgeers JL & Gerhards MF (2006). Laparoscopic resection of a symptomatic gastric diverticulum: a minimally invasive solution. *Journal of the Society of Laparoendoscopic Surgery*, **10**(4): 525-527.
- Elliott S, Sandler AD, Meehan JJ & Lawrence JP (2006). Surgical treatment of a gastric diverticulum in an adolescent. *Journal of Paediatric Surgery*, **41**(8): 1467-1469.
- Gockel I, Thomschke D & Lorenz D (2004). Gastrointestinal Gastric diverticula. *Journal of Gastroenterology and Hepatology*. **19**(2): 227.
- Johanna CC (2002). An endodermal cyst: the result of a congenital intestinal malformation. *Canadian Veterinary Journal*, **43**(9): 712-714.
- Keith A. (1910). A demonstration on diverticula of the alimentary tract of congenital or of obscure origin: Given at the Royal college of Surgeon, London. *British Medical Journal*, **1**(2563): 376-380.
- Knoefel WT & Rattner DW (2001). Duodenal diverticula and duodenal tumours. In: *Oxford Textbook of Surgery*, (Morris PJ & Wood WC, Editors). Second edition. Oxford University Press, Oxford. Pp 943-946.
- Kubiak R & Hamill J (2006). Laparoscopic gastric diverticulectomy in a 13-year-old girl. *Surgical Laparoscopic Endoscopic and Percutaneous Techniques*, **16**(1): 29-31.
- Louis N & Morris S (1936). Diverticulum of the Cardiac End of the Stomach. *Radiology*, **26**(3): 326-330.
- Marshall WS & Hayes MJ (1966). An unusual congenital abnormality in the dog. *Veterinary Record*, **79**(17): 483-484.
- McKay R 2005. Laparoscopic resection of a gastric diverticulum: a case report. *Journal of the Society of Laparoendoscopic Surgeons*. **9**(2): 225-228.
- Moses WR (1946). Diverticula of stomach. *Archives of Surgery*, **52**(1): 59.
- Olokoba OB, Ogunmodede JA, Obateru OA, Yusuf M, Bamidele ON & Agbede OE (2008). Gastric diverticulum: A Case Report. *Nigerian Medical Journal*, **49**(4): 104-105.
- Rashid F, Aber A, & Iftikhar SY (2012). A review on gastric diverticulum. *World Journal of Emergency Surgery*, **7**(1): 7922-7927.
- Van Klaveren NJ, Grinwis GC, Brocks BA & Kirpensteijn J (2008). Collapse following gastrointestinal bleeding secondary to a congenital duodenal diverticulum in two littermate boxer pups. *Journal of Small Animal Practice*, **49**(2): 103-106.