



### Orofacial Surgical Emergencies

#### *Orofacial Cas D'urgence Chirurgicaux*

O. Akpata

#### ABSTRACT

**BACKGROUND:** Orofacial surgical emergencies pose severe hazard to the individual. Medical and Dental clinicians should be able to recognise these conditions and initiate appropriate management before referral.

**OBJECTIVE:** This article presents the common orofacial surgical emergencies and the initial measures for treatment, before referring to a specialist dental surgeon for definitive treatment.

**METHODS:** Literature and related texts on the common orofacial surgical emergencies and the general principles for its management were reviewed.

**RESULTS:** Acute dental abscess, trauma, bleeding and pain in the orofacial region are the most common orofacial surgical emergencies. They usually present first to the general dental or medical practitioner, who may be required to diagnose and render initial care to these patients. Thereafter, there may be need for referral to the appropriate specialties in dentistry to help treat these severe distressing and or life-threatening conditions.

**CONCLUSION:** There is need for general medical or dental practitioners to be well-informed about the common orofacial surgical emergencies and how to diagnose, as well as provide initial treatment for these emergencies. However, the failure of clinicians to promptly diagnose and call for the assistance of a specialist dental surgeon when appropriate may result in fatal consequences. *WAJM* 2011; 30(5): 313–318.

**Keywords:** Orofacial, surgical, emergencies, dental/medical practitioners.

#### RÉSUMÉ

**CONTEXTE:** Orofaciales urgences chirurgicales posent des risques graves pour l'individu. Cliniciens médicaux et dentaires devrait être capable de reconnaître ces conditions et d'initier une gestion appropriée avant la saisine.

**OBJECTIF:** Cet article présente les communes orofaciales urgences chirurgicales et les mesures initiales pour le traitement, avant de renvoyer à un chirurgien dentiste spécialiste pour un traitement définitif.

**MÉTHODES:** textes Littérature et connexes sur les communes orofaciales urgences chirurgicales et les principes généraux de sa gestion ont été examinés.

**RÉSULTATS:** aiguë abcès dentaire, un traumatisme, les saignements et la douleur dans la région orofaciale sont les plus courantes orofaciales urgences chirurgicales. Ils se présentent généralement d'abord le médecin généraliste dentaire ou médical, qui peut être nécessaire pour diagnostiquer et de rendre les premiers soins à ces patients. Par la suite, il peut être nécessaire pour le renvoi à des spécialités appropriées en dentisterie pour aider à traiter ces conditions pénibles et graves ou mortelles.

**CONCLUSION:** Il est nécessaire de médecins généralistes ou dentaires d'être bien informé sur les communes orofaciales urgences chirurgicales et la façon de diagnostiquer, ainsi que de fournir le traitement initial pour ces situations d'urgence. Cependant, l'échec des cliniciens à diagnostiquer rapidement et appellent à l'aide d'un chirurgien dentiste spécialiste, le cas échéant peut entraîner des conséquences fatales. *WAJM* 2011; 30(5): 313–318.

**Mots-clés:** Orofaciales, la chirurgie, les urgences, les praticiens dentaires / médicaux.

## INTRODUCTION

Orofacial surgical emergencies are potentially as hazardous as medical emergencies.<sup>1</sup> They are severe distressing and/or life-threatening conditions in dentistry, where operative treatment is the cure and drugs such as antibiotics or analgesics are only adjunctive therapy.<sup>2</sup> Therefore, immediate intervention of a general dental or medical practitioner and when available, a specialist dental surgeon is required to help diagnose and treat these conditions.<sup>3</sup> The most common orofacial surgical emergencies are acute dental abscess, trauma, bleeding and pain.<sup>3-5</sup> The prevalence of these events remains uncertain, although Lipton *et al.*<sup>6</sup> reported 22% orofacial pain and 12% toothache in a general population in the United States. In addition, Adams *et al.*<sup>7</sup> reported that American students missed 1.61 million school days because of acute dental problems.

Dental practitioners have the professional responsibility to provide emergency care.<sup>8</sup> Therefore, dental clinics should be equipped to handle medical and orofacial emergencies to save life and for medico-legal reasons.<sup>9</sup> In the absence of a specialist dental surgeon, a general dental or medical practitioner may help to diagnose and treat these patients.<sup>5</sup> However, most orofacial emergencies present first to general dental or medical practitioners, on the implied assumption that they are capable of managing any event.<sup>10</sup> Therefore, medical and dental clinicians should be trained to recognise and carry out initial management of these orofacial emergencies;<sup>11</sup> which necessitates adequate undergraduate education and regular postgraduate update course on the management of acute medical and dental conditions.<sup>9</sup>

The purpose of this article is to review the orofacial surgical emergencies that commonly present to both dental and medical practitioners, and the initial measures for treatment, before referral to a specialist dental surgeon for definitive treatment when indicated.

## Common Orofacial Surgical Emergencies

The most commonly encountered

orofacial surgical emergencies include infections, trauma, bleeding, malignant neoplasm and painful conditions in the orofacial region (Table 1).<sup>3</sup>

### Orofacial Infection:

*Acute dental abscess*, particularly from the lower second and third molars, may lead to cellulitis that spreads into the facial connective tissue spaces. This may result in Ludwig's angina involving the submandibular and sublingual spaces bilaterally, and may extend to the submental space. The clinical finding is a painful massive brawny swelling, involving the floor of the mouth, parapharyngeal space and upper neck; occasionally, it may involve the mediastinum. The major risk is airway obstruction due to limited mouth opening, protruding tongue and oedema of the glottis. The condition is rapidly fatal following respiratory obstruction or later, infection in the mediastinum.<sup>12-17</sup> (Figure 1).

*Cavernous sinus thrombosis* is one of the most serious complications that

arise from infection in and around the jaws. Infections from the upper teeth and upper lip furuncle or carbuncle may spread to the orbit resulting in orbital cellulitis. Further spread of infection or thrombi in the anterior facial vein through the ophthalmic veins to the cavernous sinus may result in the cavernous sinus thrombosis and brain abscess.<sup>18</sup> Infection from both upper and lower teeth may also spread through the pterygoid plexus to the cavernous sinus. The clinical features are mainly rigors, high swinging temperature, sweating, rapid pulse and pulsating exophthalmos.

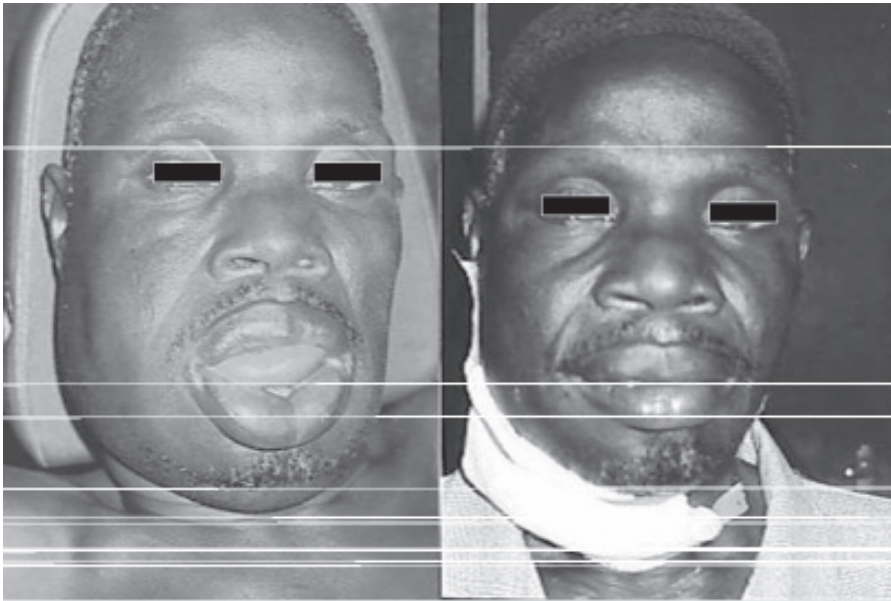
The treatment for orofacial infections such as acute dental abscess and cavernous sinus thrombosis includes immediate hospital admission of patient, together with the administration of analgesics and antibiotics which help to control pain and infection.<sup>8</sup> Pus specimen should be collected by swabbing or needle aspiration for microscopy, culture and sensitivity (M/C/S), before carrying out incision and drainage of the abscess, with rubber drains placed deep into the

**Table 1: Common orofacial surgical emergencies**

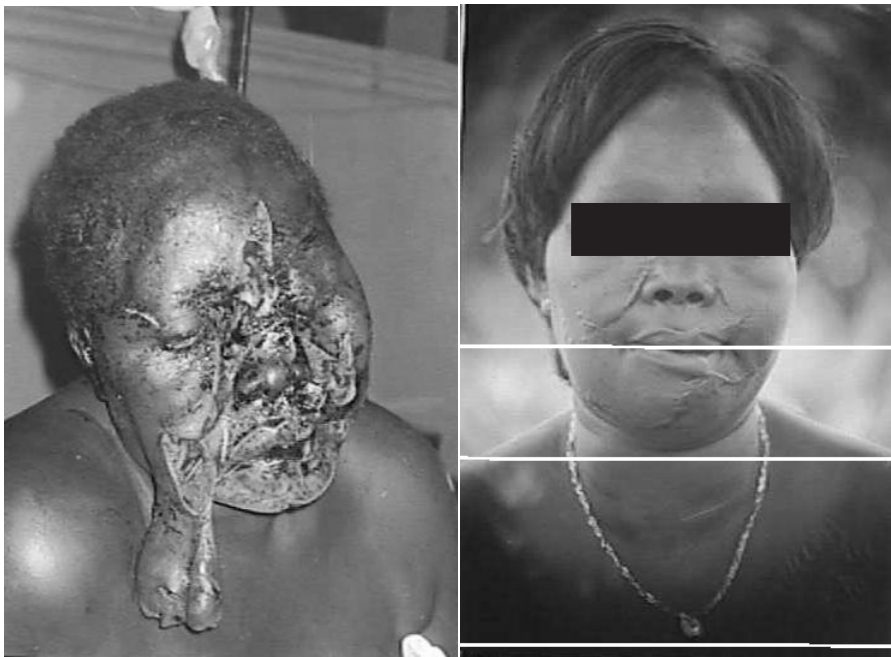---

•	<b>Orofacial infection</b>
	– <i>Acute dental abscess (Ludwig's angina)</i>
	– <i>Cavernous sinus thrombosis</i>
•	<b>Orofacial trauma</b>
	– <i>Facial fractures (zygomatic bilateral parasymphiseal fracture or condylar fractures)</i>
	– <i>Dento-alveolar injuries</i>
	– <i>Facial soft tissue lacerations (especially facial, maxillary or superficial temporal artery)</i>
•	<b>Bleeding conditions</b>
	– <i>Haemangioma</i>
	– <i>Acute leukaemia</i>
	– <i>Haemophilia</i>
•	<b>Orofacial malignant neoplasm</b>
	– <i>Osteosarcoma of the jaws</i>
	– <i>Burkitt's lymphoma</i>
	– <i>haemangiopericytoma</i>
•	<b>Orofacial pain</b>
	– <i>Dental pain (acute pulpitis, periapical periodontitis or dental abscess)</i>
	– <i>Neuralgias</i>
	– <i>Temporomandibular (TMJ) dislocation</i>
	– <i>Severely displaced jaw fracture</i>
	– <i>Infected cyst</i>
	– <i>Infected tumours</i>

---



**Figure 1: Typical Ludwig's angina with bilateral submandibular swelling and sublingual swelling with protruded tongue (Left). Complete resolution of the abscess after treatment is the rule (Right).**



**Figure 2: Severe laceration of the lower lip, forehead and cheek (A) and post-operative appearance of the patient (B)**

facial abscess. This is carried out after administration of local anaesthesia or general anaesthesia (preferably with tracheostomy for Ludwig's angina with airway obstruction) and any offending tooth should be extracted.<sup>17,18</sup>

### Orofacial Trauma and its Types

Trauma in the orofacial region occurs mostly due to road traffic accident,

gunshots, domestic accident, industrial accident, bite, sport injuries,<sup>19</sup> and iatrogenic injuries. Examples of orofacial trauma are facial fractures including dentoalveolar injuries, and soft tissue laceration.

*Facial fractures:* Middle third fractures may be associated with the risk of airway obstruction due to blood clot and swelling following the movement of

the entire mid-face downwards and backwards along the skull, resulting in lengthening of the face.<sup>20-22</sup> Zygomatic fracture with displacement of fracture fragment (orbital rim) may lead to ocular damage. Furthermore, mandibular fracture particularly, bilateral parasymphiseal fracture that is severely displaced may result in airway obstruction. This is very critical when the patient is unconscious. Condylar fracture may perforate into the external auditory meatus or middle cranial fossa.<sup>3,11</sup> Dentoalveolar injuries such as tooth avulsion especially in children and luxation or fracture may occur as isolated condition or in association with facial bone fracture.<sup>23-26</sup>

*Soft tissue laceration:* This may result in significant loss of facial soft tissue as well as severe bleeding from facial, maxillary or superficial temporal artery. However, isolated facial injuries rarely cause sufficient bleeding to induce hypovolaemic shock.<sup>8,11</sup> Gun shot injuries and lacerated major orofacial vessels during implant procedure<sup>27</sup> or third molar extraction<sup>28</sup> are exceptions, which can cause excessive bleeding.

The first consideration in management of facial trauma is the airway, which includes aspiration of blood and saliva, and removal of blood clot, foreign body/dentures or tooth fragment from the airway. Avulsed tooth is kept in a storage media such as saliva (in the buccal sulcus in the mouth of conscious patient), ice cool milk or saline.<sup>26</sup> In unconscious patients, suture is passed in the tongue as traction to prevent the tongue from falling backward and possibly causing obstruction of the airway. Disimpaction movement repositions the postero-inferiorly displaced middle third of the face. Airway tube (oral, nasopharyngeal or endotracheal) should be in place. Conscious patients are positioned in an upright sitting position, while unconscious patients are nursed in left lateral position. The associated bleeding following orofacial trauma is controlled by applying pressure dressing with gauze, nasal packing and bandage/tensor tape to bleeding site. Otherwise, the bleeding vessels are ligated with suture and any soft tissue laceration sutured.

In addition, the circulation is evaluated by examination of pulse, blood pressure and auscultation of the heart. Intravenous infusion of Ringer's® solution may be necessary, especially if the patient is in shock, unconscious or in severe orofacial injury preventing oral intake of food and drug. Drug administration following orofacial trauma includes analgesics, but opioids/morphine should be avoided to prevent respiratory depression. Other useful medications are antibiotic therapy and tetanus prophylaxis. The patient's level of consciousness should continue to be evaluated (using Glasgow coma scale). Further investigation with computerised tomography of the skull may be necessary for moderate or severe head injury.

After initial resuscitation of the patients with facial fractures and dentoalveolar injuries, these patients should be referred to Oral-maxillo-facial services and related specialists for definitive treatment.<sup>26,29,30</sup>

### Bleeding Conditions

Most orofacial bleeding is due to gingivitis or trauma, but prolonged bleeding may be due to conditions associated with bleeding tendency.<sup>3</sup> Examples of life-threatening bleeding conditions are haemangioma, acute leukaemia, and haemophilia. *Haemangioma* is a vascular malformation that may result in severe bleeding following tooth extraction or incisional biopsy in the orofacial region. Acute leukaemia may present as pallor, fine petechial haemorrhages, bruising and ulcer around the mouth, or gingival swelling.<sup>31</sup> Severe bleeding may occur spontaneously or following tooth extraction. *Haemophilia*

is a bleeding disorder due to deficiency of clotting factors viii or ix deficiency; it may present as severe bleeding from oral mucosa or alveolar socket, following trauma to orofacial tissues or tooth extraction.

The initial treatment for the bleeding conditions includes application of tight dressing gauze (pack) and suturing of mucosa or skin laceration. While haemangioma requires injection of boiling water as sclerosing solution, use of cryosurgery, arterial ligation (such as ligation of facial artery or its branches) and irradiation for severe/repeated haemorrhage from site of the lesion. Acute leukaemia requires proper oral hygiene (including mouth rinse with 0.2% chlorhexidine or tetracycline and amphotericin) and antibiotic therapy to prevent secondary infection. Folinic acid is administered to prevent bleeding resulting from methotrexate used for chemotherapy. Tooth extraction should be avoided to prevent bleeding, anaemia and infection, but if unavoidable; the procedure could be carried out under antibiotic cover and blood transfusion.

### Orofacial Malignancies

Rapidly growing facial swellings usually requires immediate referral to Oral/Maxillofacial Surgeons for diagnosis and definitive treatment. Examples of these lesions are osteosarcoma, Burkitt's lymphoma and haemangiopericytoma of the jaws. *Osteosarcoma of the jaws*, especially the mandibular lesion may cause severe haemorrhage, disfigurement and disability. The clinical features of early lesion are tooth mobility, bleeding and later, facial swelling. *Burkitt's lymphoma* occurs commonly in children

and is rapidly fatal, if not properly managed. It may involve the antrum and the orbit, causing secondary infection or bleeding. Often times, patient's referral to Oral-maxillofacial Surgeons is for biopsy and sometimes, for debulking of large lesion. *Haemangiopericytoma* is a malignant vascular tumour that is life-threatening because of the associated severe bleeding when the lesion is incised. The condition requires immediate referral to Oral/Maxillofacial surgeon for management.<sup>32</sup>

The initial treatment for neoplastic orofacial lesions involves administration of antibiotics and analgesic to control secondary infection and pain. This should be followed by incisional biopsy under local anaesthesia for the diagnosis; particularly, for Burkitt's lymphoma before chemotherapy. Extensive osteosarcoma requires jaw resection under general anaesthesia. Haemangiopericytoma also requires surgical biopsy, embolization and subsequent surgical excision of the lesions.<sup>32</sup>

### Orofacial Pain

The dental sources of pain include acute pulpitis, acute periapical periodontitis and periapical abscess. Acute pulpitis is a spontaneous poorly localised throbbing pain, which is exacerbated by temperature changes. Acute periapical periodontitis is a severe spontaneous pain from the root apex of a tooth that is exacerbated by biting on the affected tooth. The sequelae of untreated painful acute pulpal or periapical infections include formation of periapical abscess, facial space cellulitis, osteomyelitis or septicaemia, which are potentially life-threatening conditions. The non-dental pain usually occurs due to neuralgias (Trigeminal or migrainous headache); temporomandibular joint dislocation associated with difficulty in mouth closure and mastication; or severely displaced jaw fracture. In addition, infected cyst or tumours may also be the cause of non-dental pain in the orofacial region.<sup>33</sup>

Administration of local anaesthesia or general anaesthesia may be necessary for repositioning (reduction) of dislocated temporomandibular joint with/

**Table 2: List and General Principles of Management of Common Orofacial Surgical Emergencies**

- 
- **The clinician should be aware and alert for possible presentation of orofacial surgical emergencies**
  - **Clinical diagnosis of the condition based on adequate history and clinical examination, and relevant investigation (if necessary).**
  - **Immediate treatment (resuscitation)**
  - **Hospital admission (if necessary)**
  - **Referral to specialist dental surgeon (if necessary)**
-

without sedation. Thereafter, the patient should be advised to avoid wide mouth opening, otherwise it may be necessary to prevent mouth opening with intermaxillary fixation wires.<sup>5</sup> The acute pulpal or periapical pain may be treated endodontically or the affected tooth should be extracted under local anaesthesia, while dental abscess, infected cyst or tumour requires incision and drainage. In addition, biopsy of the infected tumour or cystic lesion is required for diagnosis and adequate surgical treatment of the lesion. Administration of analgesic and antibiotics may be required as adjunctive therapy to control the associated pain and infection in these conditions.<sup>2,3,33</sup>

### General Principles of Management of Orofacial Surgical Emergencies

In addition to the specific initial treatment measures for orofacial surgical emergencies outlined above, it is necessary to emphasize the general principles for managing these emergencies, especially in general dental and medical practices (Table 2). The clinician should be aware and alert to the possibility of orofacial surgical emergencies presenting as patient's complaint or as a complication following dental procedure.

It is important to take appropriate history and to examine the patient properly for quick diagnosis of the condition. However, relevant investigation should be carried out; fractures, orofacial tumours and cystic lesions should be assessed using radiographs (posterior-anterior, occipitomenal, oblique lateral and panoramic skull views). In addition, orofacial tumours and cystic lesions require surgical biopsy. The orofacial infective agents should be diagnosed using microscopy, culture, and sensitivity. Bleeding diathesis requires blood grouping/cross matching and haemostatic function tests (bleeding time, prothrombin time, activated partial thromboplastin time, and clotting factor assay). In addition, acute leukaemia requires assessment of full blood count with platelet, white blood cells and differential, blood picture and bone marrow aspiration.

The immediate resuscitative

measures for orofacial surgical emergencies have been briefly outlined in the preceding section. Patients suffering from infections, bleeding, fractures and pain in the orofacial region require initial treatment before referral for definitive treatment. Most orofacial surgical emergencies require hospital admission. However, painful orofacial conditions may require control of the pain and any associated infection, while hospital admission may be deferred until the time for definitive surgical treatment.

Although general medical and dental practitioners should be engaged in the initial management of orofacial surgical emergencies, facial fractures, rapidly spreading orofacial cellulitis and malignant neoplasms require immediate referral to Oral/Maxillofacial surgeons and related specialties.<sup>34,35</sup>

In conclusion, we have enumerated the common orofacial surgical emergencies and emphasises the need for general medical or dental practitioner to be well informed on how to diagnose and provide initial treatment for these emergencies. The failure of clinicians to promptly diagnose and call for the assistance of a specialist dental surgeon when appropriate may result in fatal consequences.

### ACKNOWLEDGEMENT:

I wish to appreciate the organizing committee of the West African College of Surgeons 2-day Workshop held from 31<sup>st</sup> January to 1<sup>st</sup> February 2005, for granting me the opportunity to present this article at the workshop in University of Benin Teaching Hospital, Benin City.

### REFERENCES:

1. Atherton GJ, Mc Caul JA, Williams SA. Medical emergencies in general dental practice in Great Britain Part 1; their prevalence over a 10-year period. *B Dent J*. 1999; **186**: 72–79.
2. Forde M P, Martin M V. Emergency prescribing. *B Dent J*. 2001; **190**: 633.
3. Robert G, Scully C, Shotts R. Clinical review: ABC of oral health, Dental emergencies. *B Med J* 2000; **321**: 559–562.
4. Ryan RN, Ware WH. Common dental emergencies that may be encountered by the family physician. *J Fam Pract*. 1975; **2**: 249–53.

5. Douglass AB, Douglass JM. Common Dental Emergencies. *American Academy of Family Physicians*. 2003; **67**: 511–6.
6. Lipton JA, Ship JA, Larach-Robinson D. Estimated prevalence and distribution of orofacial pain in the United States. *J Am Dent Assoc* 1993; **124**: 115–21.
7. Adams PF, Hendershot GE, Marano MA. Current estimates from the National Health Interview Survey, 1996 Hyattsville, Md; U.S. Department of Health and Human services, Center for Disease Control and Prevention, National Center for Health Statistics, DHHS publication; 99–1528.
8. Dailey YM, Martin MV. Are antibiotics being used appropriately for emergency dental treatment? *B Dent J* 2001; **191**: 391–393.
9. Edmondson HD, Frame JW. Medical Emergencies in General Practice 1. Acute Medical Problems. *Dental Update* 1984: 211–220.
10. Peskin RM, Siegeiman LI. Emergency cardiac care: moral, legal and ethical considerations. *Dental Clinics of America* 1995; **39**: 677–688.
11. Comer RW, Fitchie JG, Caughman WF, Zwemer JD. Oral trauma. Emergency care of lacerations, fractures, and burns. *Postgrad Med*. 1989; **85**: 34–37, 41.
12. Winters S. A review of Ludwig's angina for nurse practitioners. *J Am Acad Nurse Pract*. 2003; **15**: 546–9.
13. Britt JC, Josephson GD, Gross CW. Ludwig's angina in the pediatric population: report of a case and review of the literature. *Int J Pediatr Otorhinolaryngol*. 2000; **52**: 79–87.
14. Little C. Ludwig's angina. *Dimens Crit Care Nurs*. 2004; **23**: 153–4.
15. Furst IM, Ersil P, Caminiti M. A rare complication of tooth abscess—Ludwig's angina and mediastinitis. *J Can Dent Assoc*. 2001; **67**: 324–7.
16. Green A W, Flower E A, New N E. Mortality associated with odontogenic infection. *B Dent J* 2001; **190**: 529–30.
17. Odusanya S A. Ludwig's angina in a Nigerian with sickle cell disease. *Nig Dent J* 1982; **3**: 3–7.
18. Li X, Tronstad L, Olsen I. Brain abscesses caused by oral infection: *Endod Dent Traumatol*. 1999; **15**: 95–101.
19. Lieger O, vonArx T. Orofacial/cerebral injuries and the use of mouthguards by professional athletes in Switzerland. *Dent Traumatol*. 2006; **22**: 1–6.
20. Pigadas N, Oliver R. Common facial fractures: 2. management. *Dent Update*. 2006; **33**: 413–6, 418–20.

21. Cawson RA, Odwell. Essentials of Oral Pathology and Oral Medicine 7<sup>th</sup> ed, p 94–96, 2001.
22. Cawson RA. Essentials of Dental Surgery and Pathology. Published by Churchill Livingstone, 4<sup>th</sup> Ed. 1984; pg 207–229, 396.
23. Flores MT, Andersson L, Andreasen JO, Bakland LK, *et al.* Guidelines for the management of traumatic dental injuries. I. Fractures and luxations of permanent teeth. *Dent Traumatol.* 2007; **23**: 66–71.
24. Flores MT, Andersson L, Andreasen JO, Bakland LK, *et al.* Guidelines for the management of traumatic dental injuries. II. Avulsion of permanent teeth. *Dent Traumatol.* 2007; **23**: 130–6.
25. Flores MT, Andersson L, Andreasen JO, Bakland LK, *et al.* Guidelines for the management of traumatic dental injuries. III. Primary teeth. *Dent Traumatol.* 2007; **23**: 196–202.
26. Ceallaigh PO, Ekanaykake K, Beirne CJ, Patton DW. Diagnosis and management of common maxillofacial injuries in the Emergency Department. Part 5: Dentoalveolar injuries. *Emerg Med J.* 2007; **24**: 429–30.
27. Weibrich G, Foitzik Ch, Kuffner H. Life threatening oral hemorrhage after implantation into the distal right mandible. [Article in German] *Mund Kiefer Gesichtschir.* 2002; **6**: 442–5.
28. Moghadam HG, Caminiti MF. Life-threatening hemorrhage after extraction of third molars: case report and management protocol. *J Can Dent Assoc.* 2002; **68**: 670–4.
29. Le BT, Holmgren EP, Holmes JD, Ueeck BA, Dierks EJ. Referral patterns for the treatment of facial trauma in teaching hospitals in the United States. *J Oral Maxillofac Surg.* 2003; **61**: 857.
30. Sherick DG, Buchman SR, Patel PP. Pediatric facial fractures: analysis of differences in subspecialty care. *Plast Reconstr Surg.* 1998; **102**: 28–31.
31. Dean AK, Ferguson JW, Marvan ES. Acute leukaemia presenting as oral ulceration to a dental emergency service. *Aust Dent J.* 2003; **48**: 195–7.
32. Deneuve S, Lézy JP, Cyna-Gorse F, Vacher C. Mandibular hemangiopericytoma, a malignant vascular tumor. *Rev Stomatol Chir Maxillofac.* 2007; **108**: 146–9.
33. Okerson JP, Falace DA. Non-odontogenic toothache. *Dent Clin North Am.* 1997; **41**: 367–83.
34. Sherick DG, Buchman SR, Patel PP. Pediatric facial fractures: analysis of differences in subspecialty care. *Plast Reconstr Surg.* 1998; **102**: 28–31.
35. Le BT, Holmgren EP, Holmes JD, Ueeck BA, Dierks EJ. Referral patterns for the treatment of facial trauma in teaching hospitals in the United States. *J Oral Maxillofac Surg.* 2003; **61**: 557–60.